



Implementing Ocular Surface Disease Treatment Strategies For Today's Cataract Patient



OSD in Today's Cataract Refractive Practice

The health of the ocular surface's importance to visual outcomes and prevalence in the population makes evaluating all patients a must.

By José L. Güell, MD

The health of the ocular surface is certainly crucial to postoperative outcomes in terms of patients' comfort, but their refractive outcomes also depend on it. Undiagnosed ocular surface disease (OSD) can lead to patients' disappointment with their quality of vision after refractive cataract surgery. The accuracy of the preoperative evaluation — accurate keratometry and biometry measurements—depends on a healthy corneal surface.

The most important factor when it comes to achieving the highest quality postsurgical visual outcomes is the quality of the tear film: the first refracting surface of the eye.

Find and Treat

There are a number of ways to identify OSD, but the key message is once you find a problem you must address it prior to surgery. My choice is to assess tear film break-up time with the HD Analyzer (Visiometrics). The device provides information about the functional status of patients' tear film, and the surgeon can add more diagnostics to pinpoint the type of disease (Figure 1).

For a patient with perhaps mild dry eye, all that is needed would be lubricating drops. Along the spectrum of disease and for a more difficult case, the strategy will be to escalate treatments.

Practical Test to Incorporate

From a practical point of view, I prefer to evaluate all patients preoperatively with the HD Analyzer, both for static and dynamic testing to determine optical quality during blinks. This easy and non-invasive test shows function without the need for subjective information.

If the lacrimal test is normal, I know independently of symptoms that the ocular surface is healthy, and the reverse is also true. If there is not good function, then without treatment, there is a chance of a suboptimal outcome. The test also helps control my treatment strategy: I can tell if it is working. If in a difficult case, I am not seeing improvement, I may recommend against a multifocal IOL, for example, or in favour of a different technology.

MGD Component of Disease

Because we know that meibomian gland dysfunction (MGD) contributes to a clinically significant proportion of OSD, (Figure 2) incorporating some type of meibography is important. There are several technologies available; I believe interferometry provides the most useful images.

Treatment of MGD consists of simple strategies based on giving a "massage" to the lids along

with a warming treatment, i.e. LipiFlow (Johnson & Johnson Vision). Many work well; surgeons should decide on their own preferences to add to the treatment algorithm. The most important message is finding OSD and treat it before surgery.

Prevalence of OSD and MGD

The OSD portion of the 2018 ESCRS Clinical Survey found that on average, respondents said 21% of their cataract surgery patients present for their preoperative consultation with OSD symptoms. Respondents may be underdiagnosing the condition, as a recent report found 80% of patients reporting for cataract surgery had OSD.¹ Dry eye may be more common than recognised. Trattler et al. reported that among patients having cataract surgery, dry eye was diagnosed previously in only 22% of patients, yet on examination, corneal staining was present in 77% of patients, and approximately 63% had a significantly reduced tear film break-up time of 5 seconds or less.²

In their 2012 study, Lemp and colleagues found an 86% distribution of MGD patients³; Cochener-Lamard and colleagues found that more than half of patients presenting for cataract surgery had MGD.⁴ In the survey, respondents noted that an average of 37% of patients have MGD as a component of their dry eye.

In the ESCRS survey, 62% and 47% of respondents said they checked ocular surface health in all cases at the laser vision correction examination and cataract surgery examination, respectively. For "yes in most cases", 22% and 30% checked the ocular surface at the laser vision correction examination and cataract surgery examination, respectively, and 10% and 21% said only when the patient presents with symptoms. There were 6% and 2% of respondents who said they never check the ocular surface health.

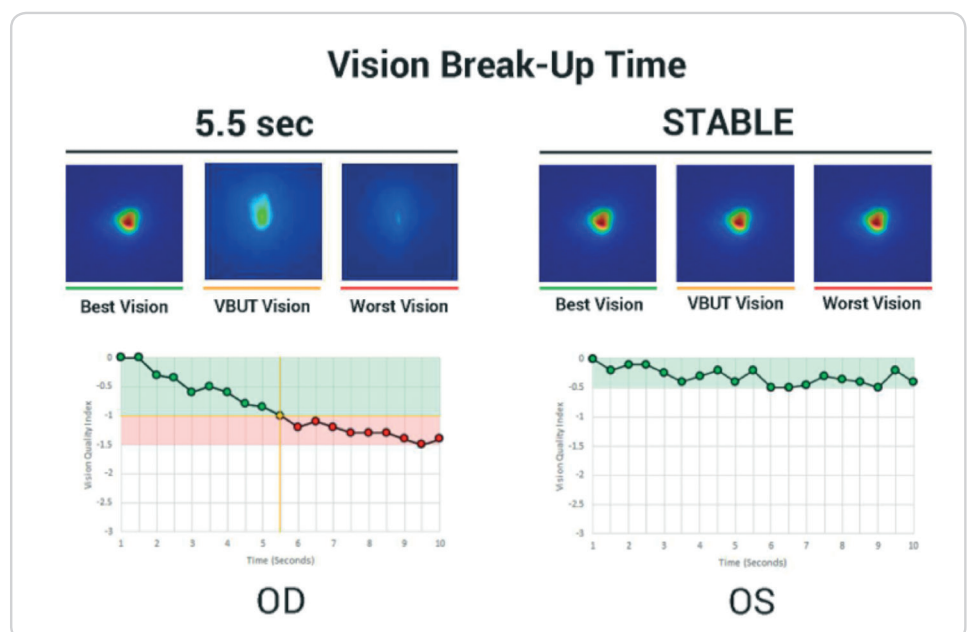


Figure 1. Assessing tear break-up time provides fast, objective, non-invasive vision fluctuation measurements

Conclusion

Undiagnosed dry eye can sabotage clinical outcomes by reducing visual quality leading to suboptimal refractive outcomes after cataract or refractive surgery. Patients are ever more demanding, expecting superior visual outcomes. To deliver on the promise of today's technology, surgeons should have a plan in place to diagnose and manage dry eye before surgery. This starts with assessing and managing the tear film.

Dr José L. Güell is a founding partner of Instituto Microcirugía Ocular of Barcelona and director of the Cornea and Refractive Surgery Department. He is past president of EuCornea and a past president of the European Society of Cataract and Refractive Surgeons. Email: guell@imo.es

References:

1. Gupta PK, Drinkwater OJ, VanDusen KW, et al. Prevalence of ocular surface dysfunction in patients presenting for cataract surgery evaluation. *J Cat Ref Surg.* 2018;44(9):1090-1096. DOI: <https://doi.org/10.1016/j.jcrs.2018.06.026>.
2. Trattler WB, et al. The Prospective Health Assessment of Cataract Patients' Ocular Surface (PHACO) study: the effect of dry eye. *Clin Ophthalmol.* 2017; 11:1423-1430
3. Lemp MA1, Crews LA, Bron AJ, et al. Distribution of aqueous-

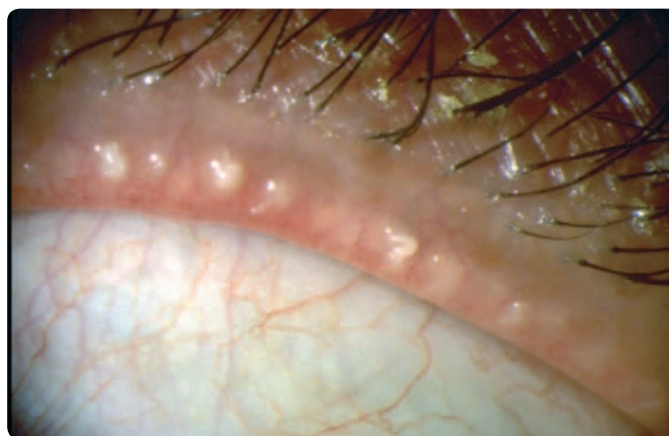


Figure 2. Meibomian gland orifices and expression of the meibomian glands

deficient and evaporative dry eye in a clinic-based patient cohort: a retrospective study. *Cornea.* 2012;31(5):472-8. doi: 10.1097/ICO.0b013e318225415a.

4. Cochener B, Cassan A, Omiel L. Prevalence of meibomian gland dysfunction at the time of cataract surgery. *J Cataract Refract Surg.* 2018;44(2):144-148.



Diagnostic Protocol for your Practice

Combine your questionnaire and slit-lamp exam with objective point-of-care data.

By Béatrice Cochener-Lamard MD, PhD

Our understanding of the underlying mechanisms of OSD has spurred the development of an increasing array of point-of-care diagnostic technology and ever-evolving treatment options. Perhaps most importantly, surgeons have a greater appreciation of the ocular surface as a key factor in visual performance and subsequent refractive cataract surgical procedures. Modern definitions of dry eye stress the multifactorial nature of the condition, notable in the TFOS/DEWSII report.¹ Contributing factors include increased tear film osmolality and inflammation of the ocular surface.

The Surface is Paramount

To ensure optimal postoperative refractive cataract outcomes, the ocular surface must be healthy. Otherwise, it can affect topography, aberrometry and keratometry measurements and may also impact on the accuracy of IOL power calculation, and axis measurements and degree of astigmatism for toric IOL implantation. This can ultimately lead to a refractive surprise and an unhappy patient.

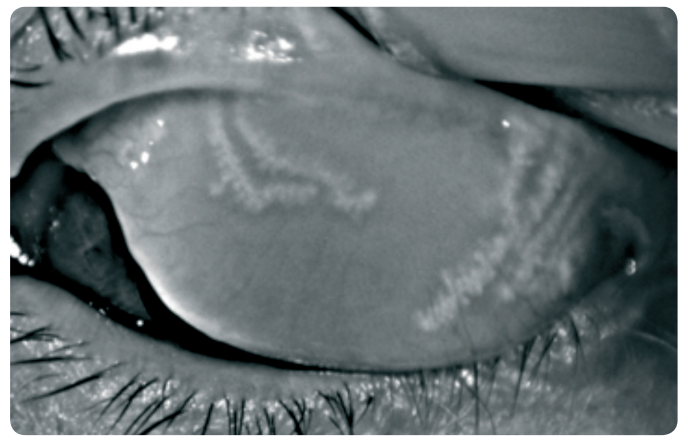
Data show that patients who present for refractive cataract surgery often have pre-existing OSD, even if it's never been diagnosed.^{2,3} It is in the best interest of patients that all surgeons carry out an assessment of the health of the ocular surface prior to any refractive cataract procedure. Treatment and resolution of

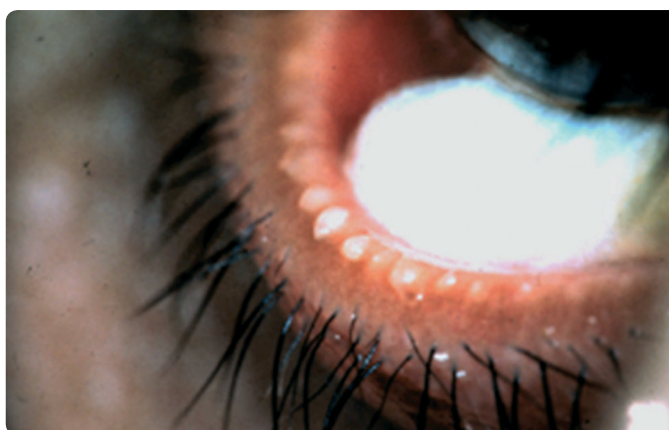

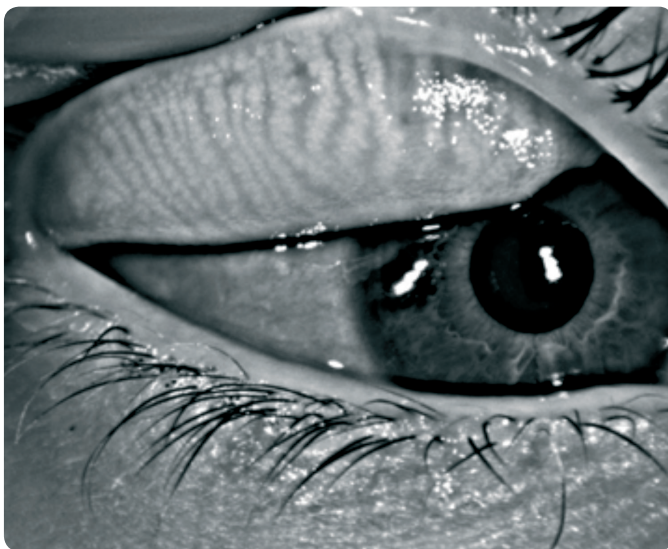Figure 3. Meibomian gland dysfunction: expression of opaque meibum

Courtesy of D. Korb

pre-existing OSD can ensure accurate results and reduce the risk of postoperative disease as well. In screening patients for preoperative dry eye, surgeons should pay attention to systemic and ocular history, contact lens use and medication history, as these factors may contribute to OSD.



Courtesy of J. Benítez-del-Castillo

Figure 4. Imaging the meibomian glands allows for an objective assessment of the meibomian glands

It is important surgeons not only look for clinical signs of dryness in preoperative examinations but that they combine the exam with patient questionnaires, like OSDI or DEQ-5, to ask about symptoms of foreign body sensation, burning, itching, stinging, lid heaviness and corneal punctate epithelial keratopathy. Symptoms may be combined with fluctuating vision, regression, decrease in best-corrected visual acuity, glare, night vision problems and severe discomfort. Risk factors to watch for before surgery include blepharitis, which can predispose patients to infection and inflammation.

Traditional Tests Being Replaced?

The traditional tests available to measure the physiological aspects of dry eye include Schirmer's test, tear break-up time and lissamine green staining. These tests lack specificity with regard to identifying the subsets of dry eye disease, and they can be difficult to perform and prone to error; therefore, newer options have been introduced. It is important, however, that surgeons make use of what tools they have at hand. Expressing the meibomian glands is crucial to see if meibum can flow and examine its consistency (Figures 3 and 4).

- **Osmolarity.** Tear film osmolarity tests (TearLab) provide an objective measure of an aqueous defect or evaporation from the ocular surface. There is a connection between tear instability and hyperosmolarity; therefore, the reading allows physicians to assess the severity of dry eye and treat patients accordingly.¹ Tear osmolarity measures can also be used to monitor patients' response to treatment.
- **Optical Quality.** The Optical Quality Analysis System (OQAS, Visiometrics) device has potential in clinical practice. Its double-pass technique measures scattering of the point spread function, which in turn can serve as a surrogate for tear film osmolarity in eyes with a clear cornea.
- **Inflammation.** InflammaDry (Quidel) can detect inflammation in a sample of tears (e.g., MMP-9) and also can provide evidence of the early presence of OSD.
- **Meibography.** LipiView interferometer (Johnson & Johnson Vision) quantifies the lipid content of the tear film and is designed to work in conjunction with the LipiFlow device to restore normal function to the meibomian gland by removing obstructions in the meibomian gland through the application of heat and gentle pulsatile pressure.



Surgeons should screen for OSD in almost all presurgical patients. Although questionnaires yield subjective information, they still should not be overlooked

It is more common than surgeons may think for asymptomatic patients to develop symptoms of OSD after surgery, particularly in the elderly population. Our investigations revealed that more than half of patients (342 eyes of 180 patients) presenting for cataract surgery had MGD identified on meibography — half were asymptomatic.⁴

Surgeons should screen for OSD in almost all presurgical patients. Although questionnaires yield subjective information, they still should not be overlooked. It is certainly key, however, to implement objective diagnostic tools to ensure a more refined diagnosis leading to an individualised therapeutic plan.

Béatrice Cochener-Lamard, MD, PhD, is Head of the Ophthalmology Department at the University Hospital of Brest, France. Email: beatrice.cochener@ophtalmologie-chu29.fr

References:

1. Craig JP, Daniel Nelson J, Azar DT. TFOS International Dry Eye WorkShop (DEWS II). *Ocular Surf.* 2017;15:269-650.
2. Trattler WB, Majmudar PA, Donnenfeld ED, et al. The Prospective Health Assessment of Cataract Patients' Ocular Surface (PHACO) study: the effect of dry eye. *Clin Ophthalmol.* 2017;11:1423-1430.
3. Gupta PK, Drinkwater OJ, VanDusen KW, Brissette AR, Starr CE. Prevalence of ocular surface dysfunction in patients presenting for cataract surgery evaluation. *J Cataract Refract Surg.* 2018 Sep;44(9):1090-1096. doi: 10.1016/j.jcrs.2018.06.026.
4. Cochener B, Cassan A, Omiel L. Prevalence of meibomian gland dysfunction at the time of cataract surgery. *J Cataract Refract Surg.* 2018;44(2):144-148.



Making Informed Treatment Decisions

Tear film break-up time is a key test to direct specific treatments

By José M. Benítez-del-Castillo, MD

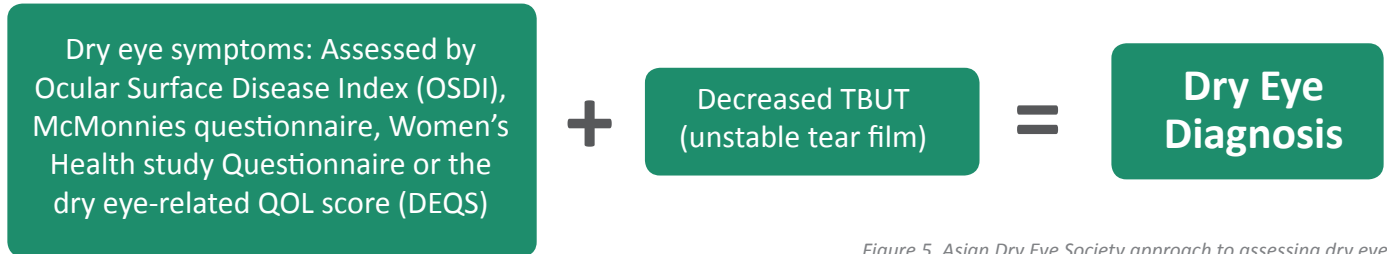


Figure 5. Asian Dry Eye Society approach to assessing dry eye

The TFOS/DEWSII guideline has provided a roadmap for identifying and treating patients with dry eye.¹ In my practice, we assess symptoms using a questionnaire, either the OSDI or the DEQ-5. If patients report symptoms, we perform three further tests:

- Osmolarity: An osmolarity of >308 mOsm/L or a difference between eyes of >8 mOsm/L is abnormal
- Tear break-up time: TBUT under 10 seconds is abnormal
- Fluorescein staining: This allows us to assess the severity of OSD

If a patient is confirmed to have dry eye, we perform a slit-lamp examination, evaluating the lid margins and expressing the meibomian glands to determine the type of OSD the patient has. For the evaporative form, I favour warm compresses and doxycycline, as well as today's newer options like LipiFlow (Johnson & Johnson Vision) and intense pulsed light.

Delay Surgery and Treat

Using a tool such as the Keratograph (Oculus) or OCT, an abnormal tear meniscus height indicates the aqueous deficient form of

dry eye. Ciclosporin is the treatment of choice, as it is indicated to increase tear film volume, along with artificial tears. With decreased tear production comes an increased risk of endophthalmitis for the patient; therefore, delaying tear clearance with punctal plugs is not a choice.

A New Type of Dry Eye?

The Asian Dry Eye Society (ADES, Figure 5) has recently adopted a very different approach to their dry eye guidelines. They use a questionnaire, such as the OSDI, and perform TBUT with fluorescein.² If the result is less than 5 seconds and the patient also has symptoms, then it is determined that the patient has dry eye. In essence, the entire diagnostic algorithm is reduced to symptoms and TBUT.

In its approach, ADES considers the tear break-up pattern, which correlate with the type of dry eye. These types are categorised and appropriate treatment regimens are described: aqueous deficient (e.g. ciclosporin, lifitegrast), mucus deficient (with corresponding treatments not available in the western countries, including mucin secretagogues diquafosol and rebamipide) or lipid deficient (e.g., thermal pulsation).

It can be useful to see a different approach to recalibrate your thinking. My approach is more aggressive when I am dealing with a candidate for lens-based refractive surgery compared with a

Treatment Considerations

- | | | |
|---|---|--|
| <ul style="list-style-type: none">• Tear substitutes/artificial tears• Dissolvable inserts• Combination medications• Artificial tears with osmoprotectants (hyperosmolar tear film)• Unpreserved steroids, ciclosporin and lifitegrast treat inflammation• Antioxidants, such as acetylcysteine, vitamin A, quercetin, gallic acid and selenoprotein P, reduce oxidative stress• Lipid supplementation for MGD/ evaporative dry eye• Adult allogenic serum for anti-inflammatory effects and to stimulate nerve regeneration | <ul style="list-style-type: none">• Oral preparations, such as ambroxol and bromhexine• Mucolytics (acetylcysteine topical drops) for patients with mucus strands• Punctal plugs or surgical punctal occlusion• Decrease evaporation with moisture chamber spectacles and humidifiers• Topical secretagogues can increase the production of aqueous, mucin and lipids• Nasal neurostimulation can increase tear production• Tea tree oil and ivermectin are used to treat Demodex | <ul style="list-style-type: none">• Warm compresses help liquefy the lipids of the meibomian glands• Thermal pulsation facilitates meibomian gland expression• Debridement scaling helps remove debris• Wearing contact lenses to prevent tear evaporation• Lubricin helps reduce friction of the eyelid against the globe• Lifitegrast 5% treats signs and symptoms of dry eye |
|---|---|--|

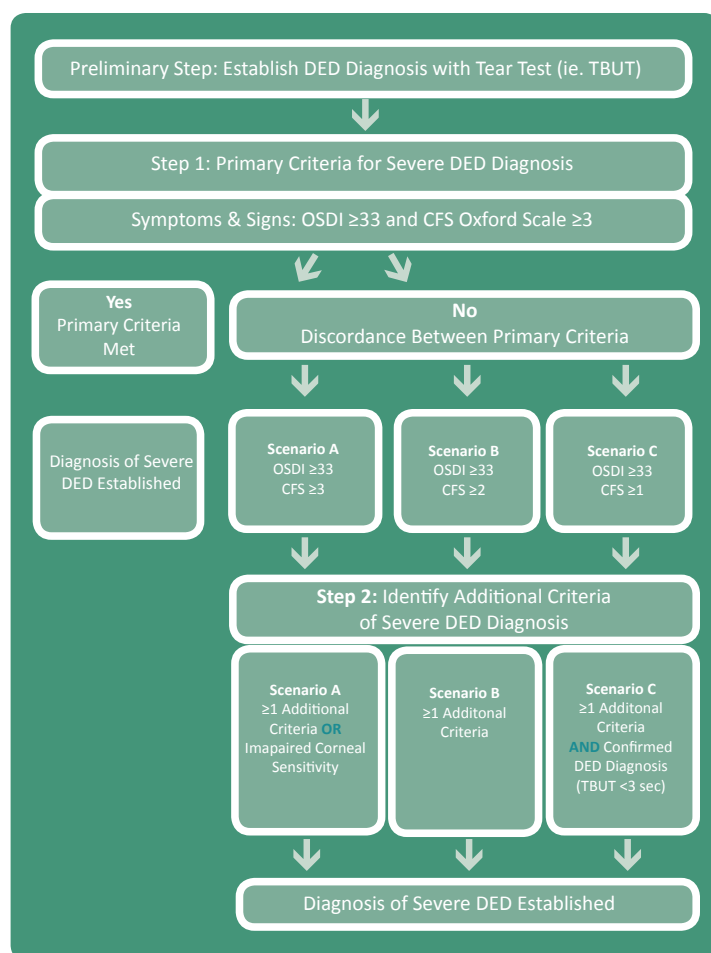


Figure 6. The ODISSEY European Consensus-derived scoring algorithm for severe DED diagnosis

“real” dry eye. It is key to understand that dry eye is a frequent complication after surgery, so it is important to inform patients properly. Educate them to the fact that it is usually transient but can be permanent.

Tear Film Break-up Time

I believe that measuring patients’ tear film break-up time is the key (Figure 6). It doesn’t matter what instrument is used — or if it is with or without fluorescein — the surgeon must know if there is a stable tear film. If the tear film is not stable, there will be resulting problems with IOL calculations and it could lead to a mistake with the chosen implant. This is the worst possible outcome for a patient who has chosen a premium technology. See the sidebar for a list of treatment considerations.

Conclusion

Importantly, patients can have signs with no symptoms due to abnormal corneal sensation. It is also possible for patients’ visual fluctuations to be caused by dry eye and not an early cataract. This reinforces the importance of evaluating all patients for OSD. Patients should have an optimal surface before and after surgery, to ensure happy outcomes.

Dr José M. Benitez-del-Castillo, MD, is chairman of ophthalmology UCM, Hospital Clinico San Carlos, Clinica Rementeria, Madrid, Spain.
Email: benitezcastillo@gmail.com

References:

1. TFOS International Dry Eye WorkShop (DEWS II). *Ocular Surf.* 2017;15:269-650.
2. Tsubota K, Yokoi N, Shimazaki J, et al. New Perspectives on Dry Eye Definition and Diagnosis: A Consensus Report by the Asia Dry Eye Society. *Ocul Surf.* 2017;15(1):65-76. doi: 10.1016/j.jtos.2016.09.003.



Case Study: Patient with Decreased Acuity

Visual changes from OSD — not a cataract.

By Francesco Carones, MD

This case demonstrates just how key the health of the ocular surface is to patients’ visual outcomes within the setting of refractive cataract surgery. In this patient, we see that ocular surface disease can cause visual disturbances in the absence of a significant cataract, that can be mistakenly attributed to changes in the crystalline lens. The case also reinforces the importance of point-of-care testing and a diagnostic work-up on patients with visual complaints.

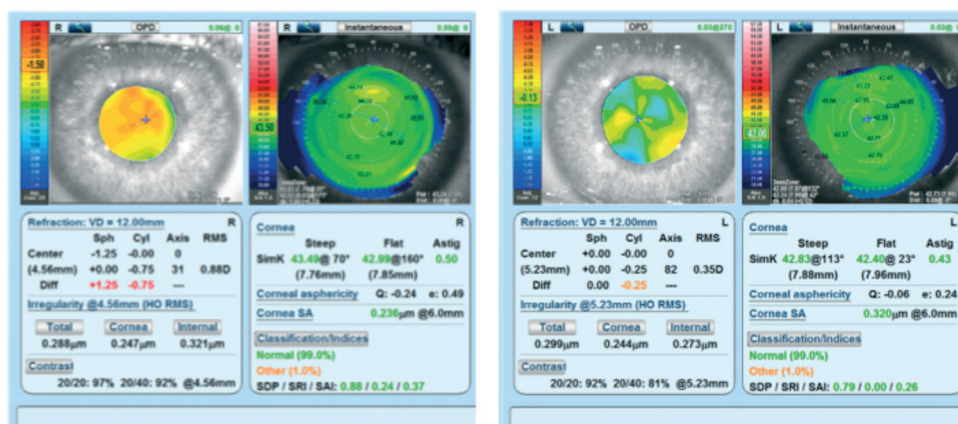


Figure 7. Patient with decreased visual acuity in the right eye

Myopic Shift

A 53-year-old male came to my office with decreased visual acuity in the right eye. Although he was diagnosed with a very early nuclear cataract, the patient's best-corrected visual acuity was still 20/20 and the other eye was fine. His visual acuity complaint was actually due to a myopic shift, not caused by opacification.

Steepening on Topography

Upon our slit-lamp evaluation, the tear film status and meibomian glands did not appear compromised. The patient noted a small amount of discomfort (OSDI score of 4), but otherwise had a normal tear break-up time and normal Schirmer staining. Because the sclerosis was evident and diagnosed early, this patient was considering cataract surgery. Upon topography, it was revealed that the right eye had a small amount of steepening and greater asphericity compared to the other eye. This uncommon finding in a normal eye triggered our attention (Figure 7).

We then performed point-of-care diagnostic tests to further evaluate the tear film, finding that the right eye had a highly hyperosmolarity reading (342 mOsm/L) along with testing positive for matrix metalloproteinase 9 (MMP-9), which was present in both eyes. Using the LipiView (Johnson & Johnson Vision), we could see meibomian gland obstruction and, most notably, the patient was unable to perform a complete blink.

Epithelial Thickness Variation

In further evaluating the tear film, we noted the epithelial thickness on the topography maps. There was a thickening of the epithelium in the centre and relative thinning in the mid-periphery, which simulates what a hyperopic laser treatment would accomplish. The thickening in the centre continues and overlaps mid periphery.

Treatment

This pattern mimics a hyperopia-like correction bringing the patient to the myopic side. This information assisted us in determining that, in this case, the visual shift was not due to nuclear sclerosis; so instead, we treated the patient for his dry eye symptoms:

- Corticosteroid drops
- Artificial tears and lubricants
- Meibomian gland expression and thermal pulsation therapy
- Tetracyclines ointment
- Ocular hygiene

The patient's uncorrected visual acuity improved significantly, going back to 20/20. His myopia reversed, his osmolarity was much improved and the MMP-9 turned negative again. This

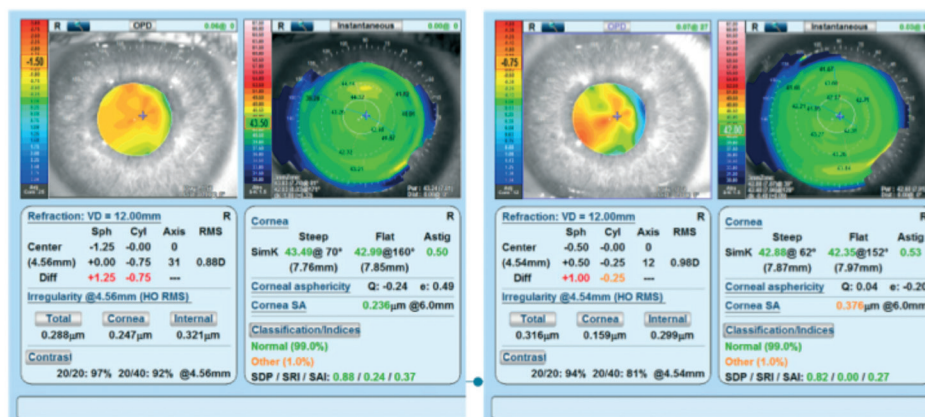


Figure 8. Patient returned to plano after treating OSD

patient regained his vision and went from myopia to almost plano, just by treating his OSD. On topography and OPD (Nidek), for the same eye, the central steepening was reversed, reducing the Q value and asphericity (Figure 8). Additionally, the epithelial thickness became more even over the corneal surface without the gradient between the centre and the mid periphery as before treatment.

The patient did not have cataract surgery. This was two-and-a-half years ago now, and I continue to see this gentleman as the condition is chronic. This patient went from a situation where no one understood what was happening with his vision, and he was headed toward scheduling cataract surgery. With no immediate cataract surgery to be done, he instead gained his vision back to his plano status just with the treatment of dry eye disease.

Conclusion

I do not like to consider what the outcomes could have been if this patient were to have had cataract surgery without appropriate OSD diagnosis and treatment. This patient stands as a classic example of Epitropoulos and colleagues' findings from an observational prospective non-randomised study in three clinical practices.¹ "Significantly more variability in average K and anterior corneal astigmatism was observed in the hyperosmolar group, with significant resultant differences in IOL power calculations," they wrote.

When patients have dry eyes or other manifestations of OSD, their key readings become unreliable. This helps us to understand that these changes in the key readings are related to the thickness of the epithelium, which in turn makes the change in the refraction of the patient.

Francesco Carones, MD, is Physician CEO and Medical Director, Carones Ophthalmology Center, Milan, Italy.
Email: fcarones@carones.com

References:

1. Epitropoulos AT, Matossian C, Berdy GJ, Malhotra RP, Potvin R. Effect of tear osmolarity on repeatability of keratometry for cataract surgery planning. *J Cataract Refract Surg.* 2015;41(8):1672-7. doi: 10.1016/j.jcrs.2015.01.016.



I do not like to consider what the outcomes could have been if this patient were to have had cataract surgery without appropriate OSD diagnosis and treatment



Supported by an unrestricted educational grant from

