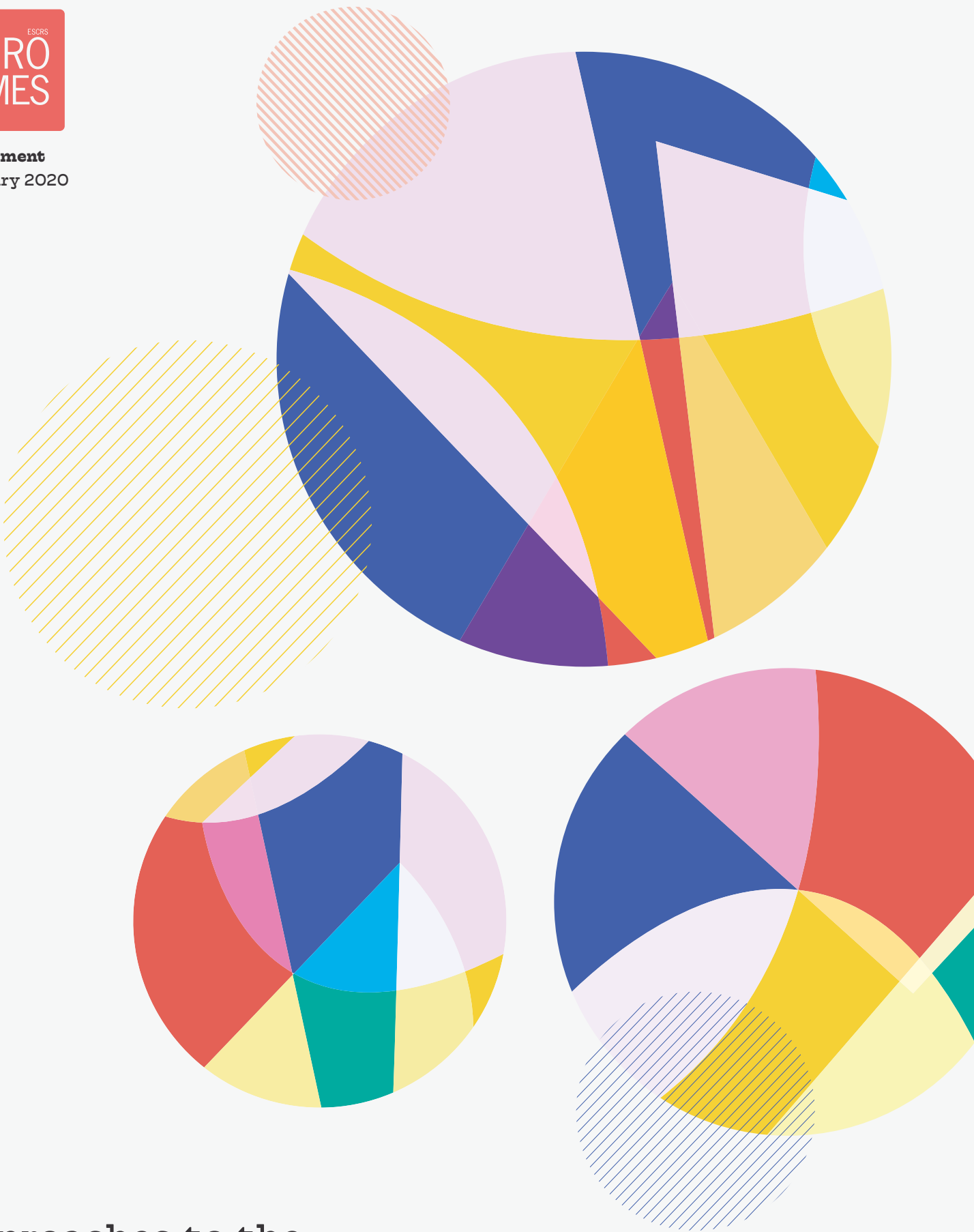

Approaches to the  
Diagnosis and Management of  
**Important Corneal Disorders**  
in the Cataract and Refractive Patient



Education  
**FORUM**



# Introduction to Baseline Trends in Corneal Cross-linking

Experts discuss the diagnosis and management of corneal disorders

By **Béatrice Cochener-Lamard, MD, PhD**

**P**reoperative diagnosis of keratoconus and ectasia is important before cataract and refractive surgery.

The 2018 ESCRS Clinical Trends Survey found that 72% of respondents exclude patients for LASIK based on their risk of ectasia using their interpretation of corneal topography; 11% use a point value as determined by the Randleman criteria; 8% use the percent tissue altered criteria; and 7% use other criteria (Figure 1).<sup>1</sup> Three per cent do not exclude patients from LASIK based on their risk of ectasia.

Thirty-three per cent of respondents perform cross-linking procedures, 18% plan to perform them within the next 12 months and nearly half have no plans to perform the procedure (Figure 2).

## NEW POTENTIAL

Corneal cross-linking is offering new hope for patients with progressive keratoconus and corneal ectasia.

It was introduced in 2003 by Theo Seiler, MD, PhD, and his colleagues, when they published a clinical pilot study using the procedure.<sup>2</sup> They instilled riboflavin drops in eyes with moderate or advanced progressive keratoconus and exposed the eyes to UVA light for 30 minutes, which halted disease progression in all eyes.

**“Corneal cross-linking is offering new hope for patients with progressive keratoconus and corneal ectasia**

Subsequently, Seiler and his colleagues reported that corneal cross-linking stopped or partially reversed keratectasia after LASIK.<sup>3</sup>

In 2015, Seiler et al. performed a study in which LASIK was performed to correct myopia in eyes with an ectasia score greater than 2, which was followed by rapid corneal cross-linking in the interface.<sup>4</sup> The study showed that superficial corneal cross-linking may be safe when performed with LASIK, but there were more temporary adverse effects and visual rehabilitation was delayed.

In addition, it should be kept in mind that the occurrence of ectasia can take several years and to report post-cross-linking results on LASIK at less than two years is not a formal guarantee of long-term stability. Therefore, care should be taken not to draw premature conclusions.

This supplement brings together top experts who will discuss the impact of keratoconus and ectasia on patient outcomes, diagnostic imaging, genetic testing and evolving cross-linking protocols for keratoconus and ectasia.

### Do you exclude patients for LASIK based on their risk of ectasia?

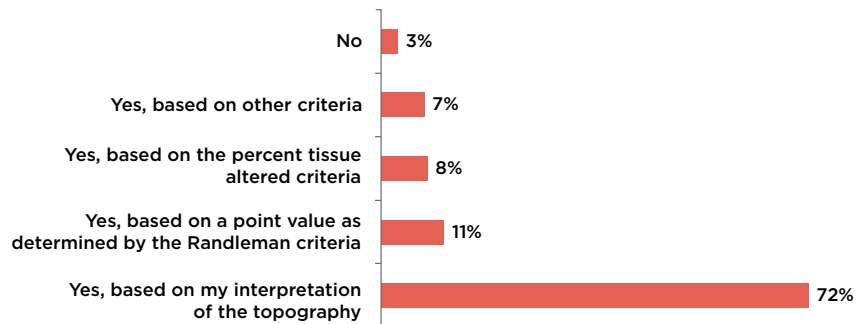


Figure 1. According to the 2018 ESCRS Clinical Trends Survey, only 11% exclude patients for LASIK based on a point value as determined by the Randleman criteria.

### Are you currently performing cross-linking procedures?

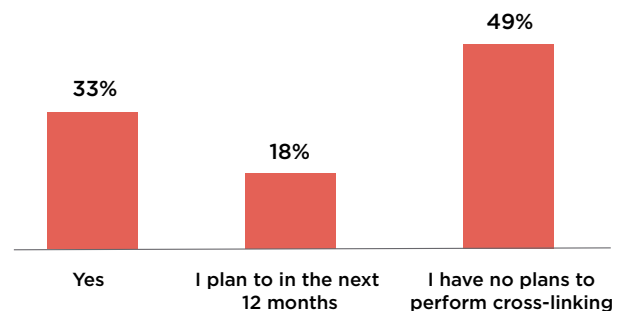


Figure 2. According to the 2018 ESCRS Clinical Trends Survey, 51% are performing cross-linking procedures or plan to in the next 12 months.

## REFERENCES

1. 2018 ESCRS Clinic Trends Survey, ESCRS Conference, Vienna, Austria.
2. Wollensak G, et al. Riboflavin/ultraviolet-A-induced collagen crosslinking for the treatment of keratoconus. *Am J Ophthalmol.* 2003; 135:620-7.
3. Hafezi F, et al. Corneal collagen crosslinking with riboflavin and ultraviolet A to treat induced keratectasia after laser in situ keratomileusis. *J Cataract Refract Surg.* 2007; 33:2035-40.
4. Seiler TG, et al. Superficial corneal crosslinking during laser in situ keratomileusis. *J Cataract Refract Surg.* 2015; 41:2165-70.

Prof Cochener-Lamard is Chair and Professor of the Ophthalmology Department at Brest University Hospital, France, General Secretary of EUCornea, and Past President of ESCRS. She may be contacted at [beatrice.cochener-lamard@chu-brest.fr](mailto:beatrice.cochener-lamard@chu-brest.fr).

Prof Cochener-Lamard is a clinical investigator for Cutting Edge, STAAR, RVO, Zeiss, Santen, Alcon, PhysiOL, Théa and Johnson & Johnson Vision.



## Diagnostic Imaging in Keratoconus

Clinicians need more than one device to diagnose irregular corneas

By George D. Kymionis, MD, PhD

**T**he prevalence of keratoconus varies widely, depending on many factors.

Research shows geographic variation in the incidence of the disease, with an increase in areas with a hot climate and abundant sunshine and a lower incidence in colder climates.<sup>1</sup> This indicates that there may be an association between ultraviolet light-induced oxidative stress and the incidence of keratoconus. It is also more likely in patients with a family history of the disease.<sup>2</sup>

Keratoconus significantly impacts patients' quality of life because of their low visual acuity, affecting mental health, social functioning and other factors.<sup>3</sup> Detrimental effects increase with disease severity.

### EARLY DIAGNOSIS

To screen for subclinical keratoconus and identify progression for potential treatment, it is essential to have diagnostic imaging technology. In addition, it is important to preoperatively screen refractive surgery candidates to exclude patients with subclinical keratoconus and evaluate premium intraocular lens candidates. Diagnostic technology is also needed to examine patients for corneal irregularities after refractive surgery to determine the need for retreatment or therapy.

Several tests are used to screen for keratoconus and ectasia: corneal topography, tomography, corneal and epithelial thickness maps, aberrometry and artificial intelligence.

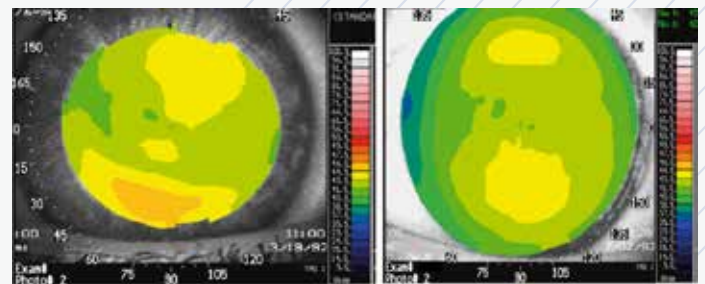


Figure 3. Slight irregularities in a corneal tomography scan. Corneal topography cannot differentiate between different causes of irregularity on the scan.

### EVALUATING DIFFERENCES

Corneal topography is the quickest, least expensive and easiest way to diagnose keratoconus. Most systems are based on Placido disc topography, which is beneficial to quickly capture a clear image. Clinicians can analyse the anterior corneal surface and stage the severity of the disease. It is also useful when examining patients with advanced keratoconus.

However, Placido-based topography is not as useful in diagnosing early-stage disease. It is limited to examining the anterior cornea, and no pachymetry data are measured. In addition, it is based on the assumption that the cornea is prolate. Non-prolate corneas or irregular corneal surfaces are often misdiagnosed as irregular,

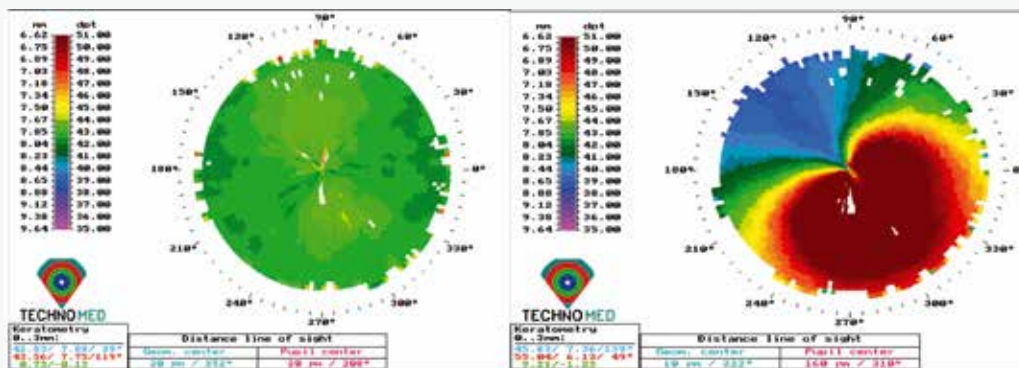
resulting in false-positive results for keratoconus. There are also difficulties when using Placido-disc topography to screen refractive surgery candidates.

Figure 3 shows slight irregularity in a corneal topography scan. Contact lens wear, technical errors during video capture, previous ocular surgery and blepharitis can cause patterns that may mimic keratoconus, resulting in false-positive or false-negative results. Corneal topography cannot differentiate between these different entities.

However, corneal tomography helps fill these gaps. We can use it to measure the elevation maps of the anterior and posterior corneal surfaces; evaluate corneal thickness, anterior chamber depth, and lens thickness/opacification; and measure higher-order aberrations.

Figure 4 shows the difference between corneal topography and tomography. The patient has forme fruste keratoconus in the right eye, with advanced keratoconus in the left eye. Although the right

### TOPOGRAPHY



### TOMOGRAPHY

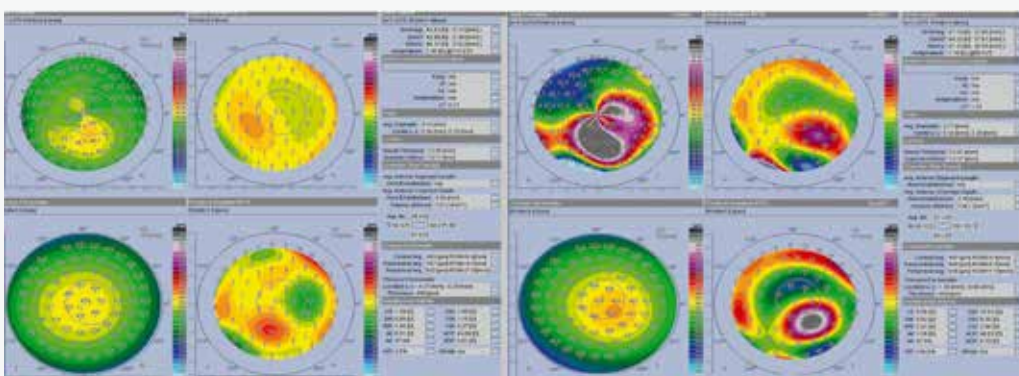


Figure 4. Comparison of corneal topography and tomography in a patient with forme fruste keratoconus in the right eye (left set of images) and advanced keratoconus in the left eye (right set of images). The right eye seems normal on corneal topography, while corneal tomography showed a pattern of subclinical keratoconus. Both exams (corneal topography and tomography) showed an advanced stage of keratoconus in the left eye.

eye may appear normal to some with corneal topography, if you examine it with corneal tomography, it shows that it also has subclinical keratoconus.

Clinical tomography additionally provides a corneal thickness map. It is very important to see the distribution of the corneal thickness along different dimensions of the cornea. We can make the differential diagnosis between subclinical keratoconus and simple corneal irregularities.

If corneal topography, tomography and corneal thickness maps do not provide enough information, we can look at epithelial thickness maps to increase the accuracy of tomography. For example, although a clinician might suspect post-LASIK corneal ectasia, the distribution of the corneal epithelial map may show that it is only epithelial hyperplasia.

We can measure higher-order aberrations of the anterior corneal surface, which is a good indicator of keratoconus and for classifying the stage of the disease. Some studies indicate that the first sign of subclinical keratoconus is increased coma and spherical aberrations. However, this is still quite challenging because with this device we cannot capture images, especially in highly aberrated corneas, and we have low reproducibility of the exams.

## CONCLUSION

The diagnosis of keratoconus is challenging, especially with early-stage disease. One imaging device alone is not a good predictor.

Most recently, artificial intelligence models have been proposed, using data from different devices to create software and algorithms to improve diagnosis. I think this will be valuable in the future in diagnosing and following patients with irregular corneas.

## REFERENCES

1. Gokhale NS. Epidemiology of keratoconus. *Indian J Ophthalmol.* 2013; 61:382-3.
2. Naderan M, et al. Association between family history and keratoconus severity. *Curr Eye Res.* 2016; 41:1414-8.
3. Kuma A, et al. Vision related quality of life in patients with keratoconus. *J Ophthalmol.* 2014; 2014:694542.

*Dr Kymionis is Professor of Ophthalmology, Jules-Gonin Eye Hospital, University of Lausanne, Switzerland. He can be contacted at [gkymionis@gmail.com](mailto:gkymionis@gmail.com).*

*Dr Kymionis has no financial interests related to his comments.*



## How Corneal Dystrophies Affect Refractive Surgery

New diagnostic tools may improve early detection

**By H. Burkhard Dick, MD, PhD, FEBOS-CR**

**B**ecause corneal dystrophies can significantly impact cataract and refractive surgery outcomes, early detection is critical. However, our efforts are impeded by the lack of affordable diagnostic tools.

### IDENTIFYING AT-RISK PATIENTS

Patients are assessed for corneal dystrophy if they have a higher risk for triggering or progression of disease: those with more than 47.0D corneal curvature or 2.0D or more astigmatism, contact lens and orthokeratology candidates, patients with a family history of keratoconus and refractive surgery candidates, in whom it is necessary to rule out corneal dystrophies. Diagnostic methods include tomography, epithelial thickness mapping, Bowman's roughness/irregularity index, and biomechanical properties (Figure 5).

With artificial intelligence and machine-learning algorithms, we can further improve our diagnostic power to detect keratoconus, but sensitivity and specificity are not very high.

Second harmonic microscopy can be used in vivo to provide precise information on collagen at different locations in the cornea using multiphoton imaging, including the intensity of the collagen, orientation, irregularity, total bundle number, intensity variance, average bundle length in each direction and the bundle number for each direction.

### ADDRESSING EQUIPMENT SHORTAGES

Approximately 75% of surgeons worldwide do not have corneal topography capabilities in their practices, so we need simple measurement techniques.

A smartphone-based auto-capture technology provides artificial intelligence-enhanced cloud-based analytics and contains an

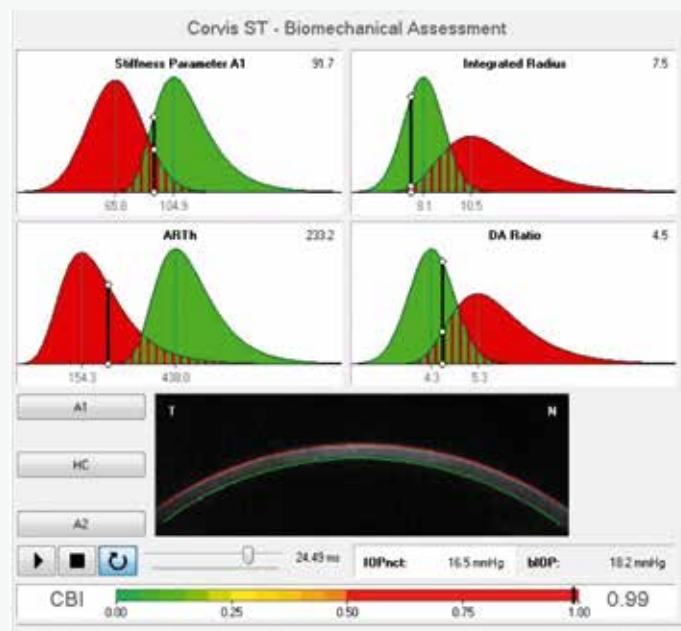


Figure 5. Biomechanical assessment with corneal visualisation Scheimpflug technology.

entire Magellan topography library. It can be attached to every slit lamp, and the software enables the clinician to perform topography and obtain information through the cloud.

Another technology focuses on transforming growth factor beta-induced protein (TGFβ1p). TGFβ1p is a common protein produced in keratocytes that binds to collagen and is upregulated during wound healing.<sup>1</sup> It is responsible for corneal dystrophies such as



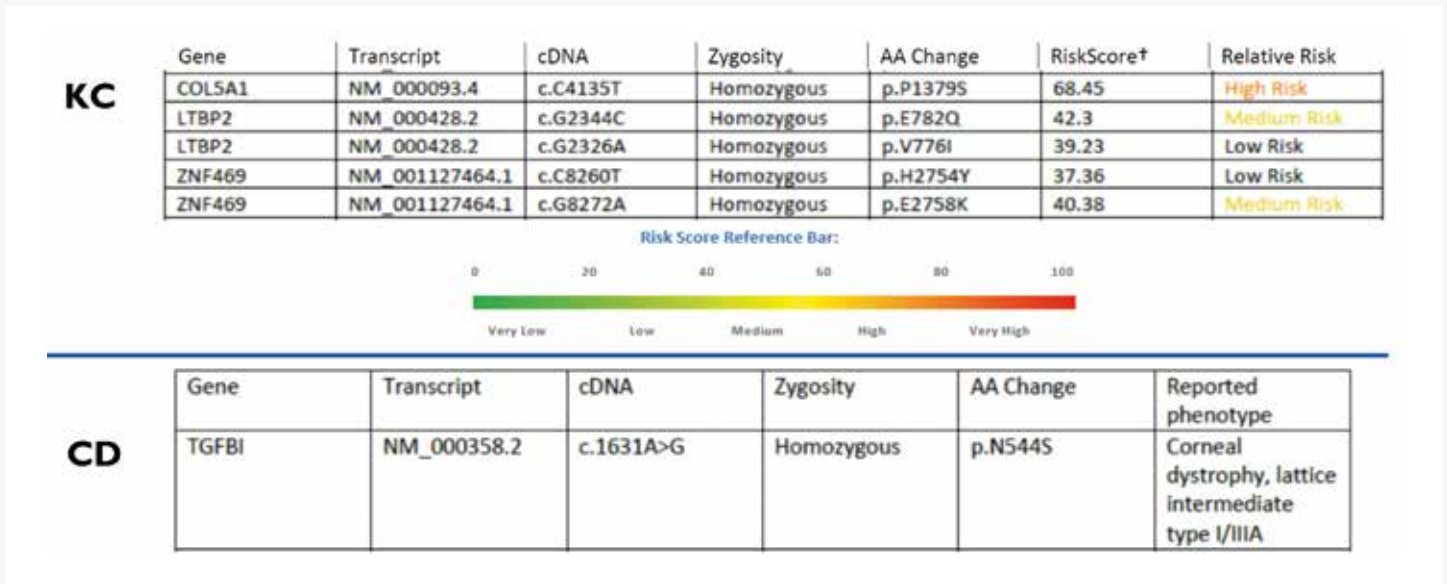


Figure 6. TGFB1 testing: Scoring results for keratoconus (KC) and description of TGFB1 corneal dystrophy (CD).

**“ Simple detection methods are needed to screen for keratoconus, and genetic tests are a valuable addition to our toolbox**

granular corneal dystrophy types 1 and 2, lattice corneal dystrophy type 1, Thiel-Behnke corneal dystrophy and Reis-Bucklers corneal dystrophy. TGFB1p corneal dystrophies show corneal cloudiness in the epithelium as well as stroma and its point mutation leads to the dystrophy.

Upregulation and the defective autophagy system, plus damage to the cornea from ultraviolet light exposure, injury, or laser or traditional surgery cause accumulation of deposits in the cornea.<sup>2,3</sup>

A test for TGFB1p was developed that initially identified one mutation in 2008 and it evolved to 11 identified mutations. These tests have been performed 750,000 times globally, detecting cases in more than 1,000 patients. The tests have 100% sensitivity and specificity.

The test is performed with a buccal swab sample that is sent for sequencing and analysis. It targets 70 TGFB1 mutations for corneal dystrophy and more than 1,000 variants across 75 genes associated with keratoconus. Individual variants receive risk scoring for keratoconus and description for TGFB1 corneal dystrophy (Figure 6).

In the future, there will be analysis of a larger number of collected positive and control samples, allowing us to have a single genetic keratoconus risk score for each patient. More detailed information on individual variants will provide greater understanding regarding keratoconus progress and risk of progression. In addition, there may be therapeutic applications based on information gained.

**“ Corneal dystrophies can seriously impact outcomes of cataract and refractive surgery, so early diagnosis is very important**

## CONCLUSION

Corneal dystrophies can seriously impact outcomes of cataract and refractive surgery, so early diagnosis is very important.

Simple detection methods are needed to screen for keratoconus, and genetic tests are a valuable addition to our toolbox. Along with existing optical and scanning methods, I predict it will help us identify at-risk patients earlier. It will improve our monitoring and help us implement preventive treatments, such as corneal cross-linking.

When performing preoperative testing before cataract or refractive surgery, it is helpful to know the patient's potential to progress to keratoconus. This will help us choose the best course of action for our patients.

## REFERENCES

1. Ween MP, et al. Transforming growth factor-beta-induced protein (TGFB1)/(Big-H3): a matrix protein with dual functions in ovarian cancer. *Int J Mol Sci.* 2012; 13:10461-77.
2. Han KE, et al. Pathogenesis and treatments of TGFB1 corneal dystrophies. *Prog Retin Eye Res.* 2016; 50:67-88.
3. Wan XH, et al. Exacerbation of Avellino corneal dystrophy after laser in situ keratomileusis. *Cornea.* 2002; 21:223-6.

Dr Dick is Director and Chairman, University Eye Hospital, Ruhr University, Bochum, Germany. He can be contacted at [burkhard.dick@kk-bochum.de](mailto:burkhard.dick@kk-bochum.de).

Dr Dick is a consultant and/or speaker for Avellino and Oculus and has intellectual property/rights and receives royalties from Oculus.



## Cross-Linking for Keratoconus and Ectasia

Researchers are investigating techniques to enhance corneal cross-linking

By Anders Behndig, MD

**T**he Dresden protocol for corneal cross-linking was introduced in 2003.<sup>1</sup> In this protocol, the central 8-to-10mm of the corneal epithelium is removed, and topical riboflavin with dextran is instilled 30 minutes before irradiation and at five-minute intervals during the 30-minute treatment. It stabilises the disease in most cases, and some patients even show improvement.<sup>2</sup>

However, corneal cross-linking is time consuming, and patients experience pain for three-to-five days.

### EXPLORING IMPROVEMENTS

Researchers have studied accelerated corneal cross-linking, but it has not been as effective as the standard protocol.<sup>3</sup> Epithelium-on procedures in room air would reduce pain, but it appears they are not as efficacious as epi-off cross-linking.<sup>4</sup> Iontophoresis-aided epi-on corneal cross-linking has been evaluated in several studies, and results have been conflicting.<sup>5,6</sup> Researchers also have tried using HPMC instead of dextran solution; HPMC provides deeper cross-linking and better results, but it also raises safety concerns.<sup>7</sup>

Standard corneal cross-linking seems effective in children, but it may not be as effective as in adults. We may be tempted to use a transepithelial approach to reduce pain in children, but it does not appear to be as effective as standard cross-linking.<sup>8</sup>



Figure 7. High-oxygen epi-on treatment in patient with myopia.

### ADDITIONAL RESEARCH

When corneal cross-linking is performed in room air, oxygen is consumed rapidly after the cross-linking light is turned on. However, if we continuously flush the cornea with oxygen, we can maintain oxygen in the cornea during the procedure. It is well known that cross-linking is oxygen dependent; greater oxygen may result in a greater effect.

In an ongoing European study, epi-on photorefractive intrastromal cross-linking in a  $96 \pm 2\%$  oxygen atmosphere seems to achieve a similar effect as epi-off treatment in room air in patients with low myopia, where the refractive effect is easy to assess (Figure 7).<sup>9,10</sup> This is not keratoconus, but results may indicate that it is worth studying.

Topography-guided cross-linking treatment (CuRV) is being studied. The goal of CuRV is to control and enhance refractive improvement after cross-linking. CuRV has shown refractive advantages compared with conventional cross-linking for keratoconus.<sup>11</sup>

In a small ongoing study, we have performed bilateral procedures, treating one eye with epi-on CuRV in higher oxygen and the other with epi-off CuRV in room air. In the beginning, epi-on pain is as intense as epi-off pain. At one or two days, epi-on pain is more tolerable, but pain persists for four or five days after epi-off cross-linking. The haze depths in epi-on and epi-off in this protocol are statistically equal.

### CONCLUSION

The Dresden protocol is still the gold standard despite some disadvantages. Highly accelerated protocols and epi-on cross-linking in room air seem to be less efficacious. Epi-on treatment in high oxygen may show promise, but more data are needed.

**“The Dresden protocol is still the gold standard despite some disadvantages**

### REFERENCES

1. Wollensak G, et al. Riboflavin/ultraviolet-A-induced collagen crosslinking for the treatment of keratoconus. *Am J Ophthalmol.* 2003; 135:620-7.
2. Wittig-Silva C, et al. A randomized, controlled trial of corneal collagen cross-linking in progressive keratoconus: three-year results. *Ophthalmology.* 2014; 121:812-21.
3. Choi M, et al. Comparison of the conventional Dresden protocol and accelerated protocol with higher ultraviolet intensity in corneal collagen cross-linking for keratoconus. *Cornea.* 2017; 36:523-9.
4. Li W, et al. Efficacy and safety of transepithelial corneal collagen crosslinking surgery versus standard corneal collagen crosslinking surgery for keratoconus: a meta-analysis of randomized controlled trials. *BMC Ophthalmol.* 2017; 17:262.
5. Jouve L, et al. Conventional and iontophoresis corneal cross-linking for keratoconus: efficacy and assessment by optical coherence tomography and confocal microscopy. *Cornea.* 2017; 36:153-62.
6. Vinciguerra P, et al. Iontophoresis CXL with and without epithelial debridement versus standard CXL: 2-year clinical results of a prospective clinical study. *J Refract Surg.* 2019; 35:184-90.
7. Thorsrud A, et al. Superior outcome of corneal collagen cross-linking using riboflavin with methylcellulose than riboflavin with dextran as the main supplement. *Acta Ophthalmol.* 2019; 97:415-21.
8. Buzzonetti L, et al. Iontophoretic transepithelial collagen cross-linking versus epithelium-off collagen cross-linking in pediatric patients: 3-year follow-up. *Cornea.* 2019; 38:859-63.
9. Fredriksson A, et al. A prospective evaluation of photorefractive intrastromal cross-linking for the treatment of low-grade myopia. *Acta Ophthalmol.* 2019 Jul 12. [Epub ahead of print]
10. Elling M, et al. Photorefractive intrastromal corneal crosslinking for treatment of myopic refractive error: findings from 12-month prospective study using an epithelium-off protocol. *J Cataract Refract Surg.* 2018; 44:487-95.
11. Nordström M, et al. Refractive improvements and safety with topography-guided corneal crosslinking for keratoconus: 1-year results. *Br J Ophthalmol.* 2017; 101:920-5.

Dr Behndig is based at the Department of Clinical Sciences/ Ophthalmology, Umea University Hospital, Sweden. He can be contacted at anders.behndig@umu.se.

Dr Behndig has no financial interests related to his comments.



# Decision Tree for Keratoconus and Ectasia

Clinicians need to navigate an increasing number of treatment options

By Mario Nubile, MD

In developing a decision tree for treatment of keratoconus, we need to keep in mind that it is a multifactorial disease. We do not understand all the factors involved, but matrix remodeling, inflammatory and genetic factors play a role.

There is an increased level of expression of some matrix metalloproteinases, such as MMP-9 and other proinflammatory cytokines.<sup>1</sup> The expression of these cytokines or metalloproteinases is increased when there are breaks, micro ruptures or micro trauma of Bowman's layer. Therefore, conditions that cause patients to rub their eyes and induce micro trauma, such as allergies or atopy, could trigger the inflammatory cascade that could worsen keratoconus.<sup>2</sup>

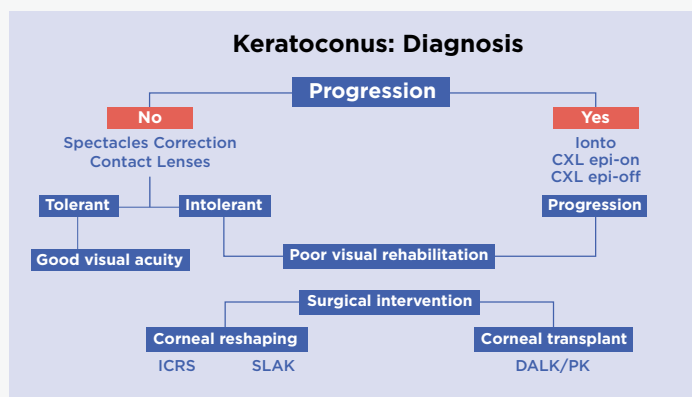


Figure 8. Decision tree after diagnosis of keratoconus.

## MANAGING KERATOCONUS

It is not enough to instruct patients not to rub their eyes. We must help patients control the symptoms that cause eye-rubbing, using treatments such as cyclosporine drops, topical steroids or antihistamines. Changing the behavior will help reduce the risk of progression, but it will not improve vision or cure keratoconus.

If a patient has progressive keratoconus, corneal cross-linking may be useful to halt or reduce progression (Figure 8).

However, if keratoconus is not progressive, we can take different steps. First, we can try spectacle correction or contact lenses. Spectacle correction, which is used for forme fruste and early forms of keratoconus, only corrects lower-order aberrations. Normal soft contact lenses work similarly. Rarely we achieve good visual quality and improve their quality of life with these methods, but if obtained, this may be acceptable.

Many types of special contact lenses are available. Custom-made rigid gas permeable (RGP) contact lenses are used most often for keratoconus. However, they might not be tolerated. Therefore, the hybrid lens was introduced, combining a soft exterior and RGP center. They provide good visual performance and may be more comfortable.

Some patients may tolerate contact lenses for only a portion of the day, which may be limiting.

## SURGICAL INTERVENTION

If the patient is intolerant to contact lenses or we are not providing good visual results, surgical intervention may be needed, beginning with corneal reshaping techniques, such as intracorneal rings or stromal lenticular addition keratoplasty. Corneal reshaping can

improve spectacle-corrected vision and contact lens tolerance.

Intrastromal corneal ring segments flatten the cornea to adjust the refraction. Only a few intracorneal ring segments have been approved by the US Food & Drug Administration or in Europe, and they can provide good results.

In a review of the literature containing approximately 1,000 treated patients, with five years of follow-up, visual acuity and refractive outcomes improved, but because all higher-order aberrations are not corrected, patients cannot achieve their full potential.<sup>3</sup> In addition, changes in the obtained effect and regression can occur over time after intracorneal ring implantation in patients with progressive keratoconus. Furthermore, corneal cross-linking may be used to stabilise the structure of the cornea after remodeling.<sup>4</sup>

In our Research Centre, chaired by Prof Leonardo Mastropasqua, we performed research showing that a donor lenticule could be implanted in the anterior part of the stroma to flatten the cornea, increasing the thickness and flattening the apex of the central cone.<sup>5,6</sup> We found that we can thicken the cornea, reducing astigmatism and aberrations, and correct a certain amount of myopia, which is common in patients with keratoconus. Long-term follow-up showed that the cornea remained very clear and we could barely see that the patient had a type of transplant surgery.

Corneal transplants should be considered when other treatments are insufficient. Results for deep anterior lamellar keratoplasty (DALK) and penetrating keratoplasty are comparable, but the safety profile of DALK is higher than that of penetrating keratoplasty.<sup>7</sup>

## REFERENCES

1. Di Martino E, et al. Matrix metalloproteinases in keratoconus—too much of a good thing? *Exp Eye Res.* 2019; 182:137–43.
2. Hashemi H, et al. The prevalence and risk factor for keratoconus: a systematic review and meta-analysis. *Cornea.* 2019 [epub ahead of print]
3. Alio JL, et al. Intrastromal corneal ring segments: how successful is the surgical treatment of keratoconus? *Middle East Afr J Ophthalmol.* 2014; 21:3–9.
4. Saelens IEY, et al. Refractive, topographic, and visual outcomes of same-day corneal cross-linking with Ferrara intracorneal ring segments in patients with progressive keratoconus. *Cornea.* 2011; 30:1406–8.
5. Mastropasqua L, Nubile M. Corneal thickening and central flattening induced by femtosecond laser hyperopic-shaped intrastromal lenticule implantation. *Int Ophthalmol.* 2017; 37(4):893–904.
6. Mastropasqua L, et al. Femtosecond laser-assisted stromal lenticule addition keratoplasty for the treatment of advanced keratoconus: a preliminary study. *J Refract Surg.* 2018; 34:36–44.
7. Yüksel B, et al. Comparison of visual and topographic outcomes of deep-anterior lamellar keratoplasty and penetrating keratoplasty in keratoconus. *Int J Ophthalmol.* 2017; 10:385–90.

Dr Nubile is based at the Excellence Eye Research Center, (Director: Prof L. Mastropasqua) University Gabriele d' Annunzio of Chieti, Pescara, Italy. He can be contacted at m.nubile@unich.it.

Dr Nubile has no financial interests related to his comments.



*Supported by an unrestricted  
medical education grant*



**Silver**

**avedro**

**Bronze**