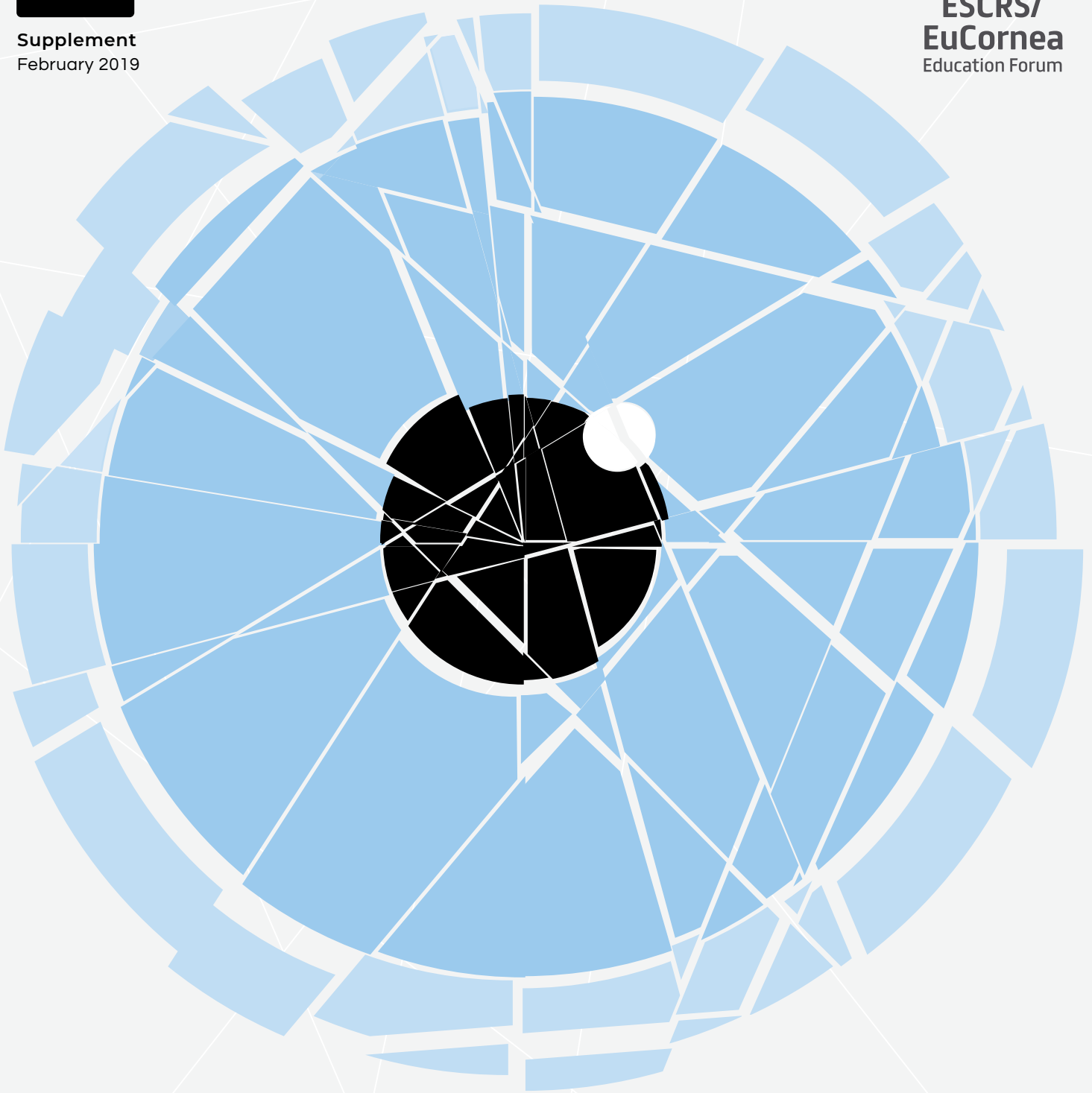




Supplement  
February 2019



ESCRS/  
EuCornea  
Education Forum



# Diagnosing and Treating Ocular Surface Disease in Surgical Patients

*Supported by an unrestricted educational grant from*





# Routine Preoperative Check of Ocular Surface on the Rise

By José L Güell MD, PhD

The incidence of ocular surface disease (OSD) among cataract and refractive surgery patients makes preoperative diagnosis and treatment imperative. A review of the 2017 ESCRS Clinical Survey regarding accurately diagnosing and effectively treating OSD in surgical patients revealed that almost 100% of respondents agree that treating dry eye prior to cataract surgery can have a significant impact on postoperative satisfaction or visual outcomes. Despite this consensus,

“ Last year fewer surgeons were systematically checking the ocular surface preoperatively suggesting that we are observing a change in the trends

advanced diagnostics are underemployed, with most surgeons using them on a case-by-case basis.

When asked if they systematically check the ocular surface in preoperative cataract surgery evaluations, 23% said they only check the ocular surface when patients present with dry eye symptoms; 42% said they always do; 30% said they almost always look at the ocular surface for telltale signs of dry eye; and just 5% said they rarely or never do. When answering this same question with regard to laser vision correction examinations, 12% of respondents said they only do when the patient presents with dry eye symptoms; 58% always do, 23% check the ocular surface in most cases, leaving just 7% admitting that they rarely or never do. (Figure 1) Last year fewer surgeons were systematically checking the ocular surface preoperatively, suggesting that we are observing a change in the trends.

A majority of surgeons – or just over 60% – responded that they are confident or very confident in their ability to effectively treat dry eye with current therapies. According to the survey, the most popular treatments for moderate dry eye are oral omega-3 and topical corticosteroids. Cyclosporine, punctal occlusion, oral omega-3 and topical corticosteroid are most often prescribed for severe dry eye; and warm compresses, commercial warm compresses and meibomian gland probing are most often used to treat meibomian gland dysfunction (MGD).

The survey revealed that surgeons are most often testing for dry eye on a case-by-case basis. Respondents indicated that limited access and cost are the primary roadblocks to incorporating advanced tear film diagnostics in their practice. When looking at combined case-by-case and initial point of care testing, in this year's survey, osmolarity testing was employed in 23% of cases; lipid layer interferometry was used in 12% of cases; and meibography was used in 20% of cases.

Last year 40% said they had limited access to advanced diagnostics; this year that number is down slightly to 38% suggesting that, while the shift is slow, methods such as osmolarity testing, lipid layer interferometry and meibography are gaining some traction.

*José L Güell MD, PhD is Associate Professor of Ophthalmology at Autònoma University of Barcelona, Spain and Director of Cornea and Refractive Surgery Unit at the Instituto Microcirugía Ocular of Barcelona (IMO), Spain.*

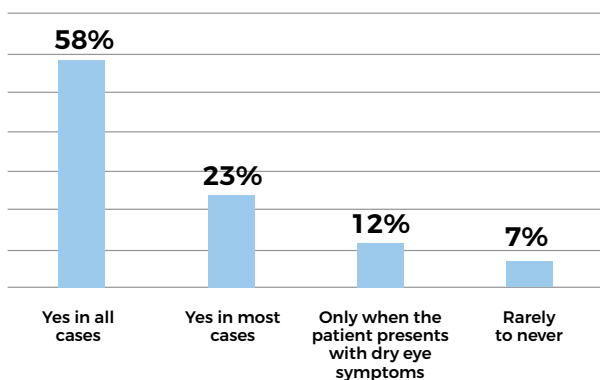
*E-mail: guell@imo.es*

*Financial Disclosures: Alcon, Ophtec, Orca Surgical, Théa, Visiometrics, and Zeiss.*

## OCULAR SURFACE

Are you systematically checking the ocular surface in your preoperative...

Laser vision correction examination?



Cataract surgery examination?

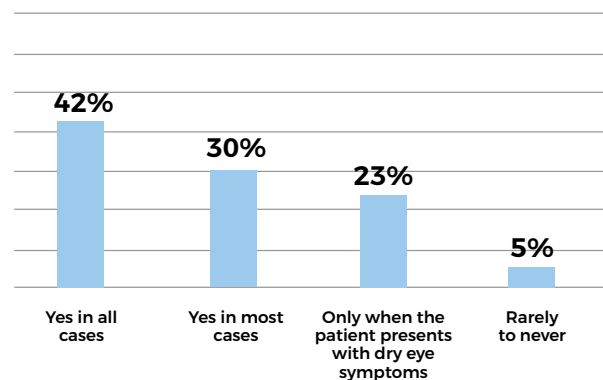


Figure 1: The majority of surveyed surgeons check the ocular surface prior to cataract and LASIK surgery



# Recognising Effects of OSD in the Cataract Surgical Setting

By Béatrice Cochener-Lamard MD, PhD

**A**s we gain greater understanding of ocular surface disease (OSD), our recognition of its impact on cataract surgery is also increasing. OSD, and meibomian gland dysfunction (MGD) in particular, is prevalent among patients undergoing cataract surgery, and the literature supports this. In one study, more than 75% of 136 cataract patients had signs of dry eye; and 86% percent of dry eye cases include an MGD component, according to another study.<sup>1,2</sup> In another trial looking at the incidence of dry eye in cataract patients, of the 233 subjects evaluated 59% had MGD.<sup>3</sup> If OSD goes undiagnosed prior to surgery, the negative impact on outcomes and quality of life could be severe.

Comprehensive preoperative testing should routinely include evaluation of meibomian function. Women have an even higher incidence of OSD according to a study of 471 perimenopausal women; it revealed that 91% had symptoms or complaints of dry eye, and 87% had MGD with either visual symptoms or visual function symptoms.<sup>4</sup> In our own study, my colleagues and I found that meibomian gland function correlated significantly with lipid layer thickness, symptoms, age, and gland atrophy.<sup>5</sup> We evaluated patients with the Standard Patient Evaluation of Eye Dryness (SPEED) questionnaire and the LipiView Ocular Surface Interferometer, slit lamp and the Meibomian Gland Evaluator to assess lipid layer thickness, blink rate and gland structure, as well as the quantity and quality of meibomian gland secretions. The study comprised 342 eyes of 180 patients; 52% of patients had MGD, and 56% had meibomian gland atrophy equal to or greater than Arita grade 1. Our findings indicate that the difference in lipid layer thickness between SPEED score

**Comprehensive preoperative testing should routinely include evaluation of meibomian function**

groups was statistically significant. The incidence of MGD was high in patients presenting for cataract surgery, and 50% of patients with MGD were asymptomatic.

The point that must be emphasised is that 49% of those who had MGD were asymptomatic before the surgery, and 40% had complaints after the surgery. This suggests that if we do not evaluate these cataract patients before surgery, then when they have dry eye complaints after surgery it will be too late to explain that their dry eye was a preexisting situation that was not related to the surgery.

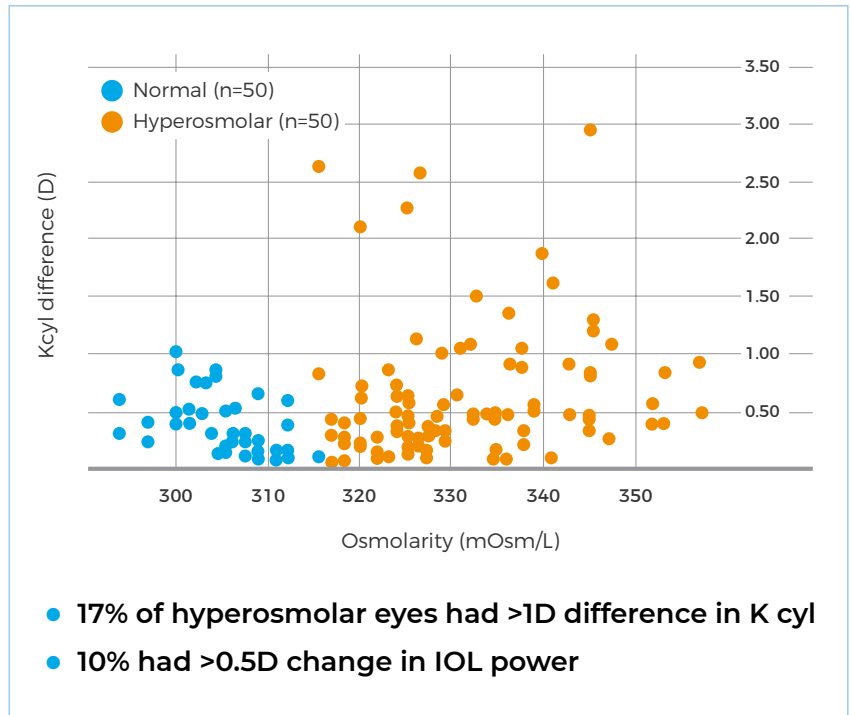


Figure 2: Significant increase in osmolarity can lead to the incorrect IOL measurement. This scatterplot shows 17% of hyperosmolar eyes had >1D difference in corneal cylinder and 10% had >0.5D change in IOL power

## OSD'S IMPACT

Failure to access and identify tear film instability results in erroneous measurement of keratometry, topography, and refraction. It can skew the axis measurement and astigmatism value, and contribute to the wrong IOL choice, especially in the case of toric lenses. Ultimately, the surgical decision will be completely impaired if the state of the ocular surface and its potential impact on visual fluctuations is not preoperatively taken into account.

Epitropoulos and colleagues demonstrated that a significant increase in osmolarity – which is correlated to inflammation – can lead to the incorrect IOL measurement.<sup>6</sup> In her study, 17% of the population had a difference of more than 1D with respect to the cylinder in kerato-based measurement, and 10% had more than 0.5D change in IOL power. (Figure 2)

The relationship between the tear film thickness and refractive power has also been well studied; it has been shown that the tear film has an optical power that relates to stability of visual performance.<sup>7-9</sup> We also know that the tear film thickness correlates to MGD and dryness. The normal blink rate is 15 times per minute; however, computer users typically do not achieve this, suggesting that an increase in MGD may be seen in computer and digital device users – a group heavily populated by young people.

Beyond visual acuity, we need to consider the quality of vision to define our patients' level of satisfaction. So in addition to manifest refraction, we must consider comfort: itching, burning, foreign body sensations. We must also

consider halos, glare, fluctuation, night discomfort – all of these can be induced by higher-order aberration and in many cases, induced by the ocular dryness.

When you have an alteration of the ocular surface, that will lead to an unstable quality of vision. Beyond epithelial damage, this will be a source of ocular dryness, and possibly a decrease of central visual acuity, ocular fatigue on the computer and a signal of OSD, which again must be taken into account.

### TREAT OSD PROACTIVELY

Surface irregularity or tear film instability is a source of impaired quality of vision. As soon as there are any visual symptoms – ranging from discomfort up to fluctuations – especially in the presbyopia-aged population, it is important to consider the health of the ocular surface and the tear film, so that these patients will be treated proactively before they present for cataract surgery.

*Béatrice Cochener-Lamard MD, PhD is the head of the Ophthalmology Department in Brest University Hospital, France.*

*E-mail: [beatrice.cochener-lamard@chu-brest.fr](mailto:beatrice.cochener-lamard@chu-brest.fr)*

*Financial Disclosure: Alcon, Cutting Edge, Hoya, Johnson & Johnson Vision, Physiol, RVO, Santen, Shire, Staar, Théa, and Zeiss.*

### REFERENCES

1. Trattler WB, et al. The prospective health assessment of cataract patients' ocular surface (PHACO) study: The effect of dry eye. *Clin Ophthalmol* 2017;11:1423-30.
2. Lemp M, et al. Distribution of aqueous-deficient and evaporative dry eye in a clinic-based patient cohort: a retrospective study. *Cornea*. 2012;31(5):472-478.
3. Algamadi et al. Epidemiology of Meibomian Gland Dysfunction in an Elderly Population. *Cornea*. 2016 Jun;35(6):731-5.
4. Jin X, et al. *Medicine (Baltimore)*. Hormone replacement therapy benefits meibomian gland dysfunction in perimenopausal women. 2016 Aug;95(31):e4268.
5. Cochener B, Cassan A, Omiel L. Prevalence of meibomian gland dysfunction at the time of cataract surgery. *J Cataract Refract Surg* 2018; 44:144-148.
6. Epitropoulos AT, Matossian C, Berdy GJ, et al. Effect of tear osmolarity on repeatability of keratometry for cataract surgery planning. *J Cataract Refract Surg* 2015;41:1672-7.
7. Pisella PJ, Baudouin C, HX Thanh, Report of the French Ophthalmological Society 2015, Surface Oculaire. *Explorations Fonctionnelles*. Chapter 2, p.101.
8. Montés-Micó R. Role of the tear film in the optical quality of the human eye. *J Cataract Refract Surg* 2007;33:1631-35.
9. Kim JS, Lee H, Choi S, et al. Assessment of the Tear Film Lipid Layer Thickness after Cataract Surgery, *Semin Ophthalmol*, 2018;33:2, 231-236.



## Current Diagnostic Tools Improve Understanding of the Ocular Surface

*By Carina Koppen MD, PhD*

It is critical to diagnose dry eye disease (DED) prior to cataract surgery because if it exists preoperatively, it will be worse afterward and the patient will think the surgery failed. It is important to mitigate dry eye prior to every cataract procedure, but perhaps even more so in the case of premium IOL implantation and refractive clear lens surgery. In these cases the expectations are even higher than usual, and the dry eye – if untreated – can skew the preoperative measurements and lead to refractive surprises and a highly dissatisfied patient.

You may think it takes all the newest diagnostic equipment to identify dry eye, but all you really need are the essentials: a detailed patient history and possibly a symptom questionnaire; a thorough slit lamp exam of the entire ocular surface, fluorescein staining and tear break-up time (TBUT).

The first and most important step is to be aware of the possibility of dry eye. Listen to the patient's symptoms, and consistently look for signs. If you see or suspect a dry eye problem tell the patient; then set realistic postoperative expectations: under-promise so you can over-deliver.

### ASK ABOUT SYMPTOMS

Taking a thorough history is as useful as utilising a symptom questionnaire; however, a tool such as the OSDI (Ocular Surface Disease Index) is a handy way to quantify symptoms and gauge improvement over time. When gathering information, remember to ask about the patient's quality of visual acuity. A dysfunctional tear film can diminish vision quality and instigate visual fluctuations throughout the day, from day to day, or even between blinks.

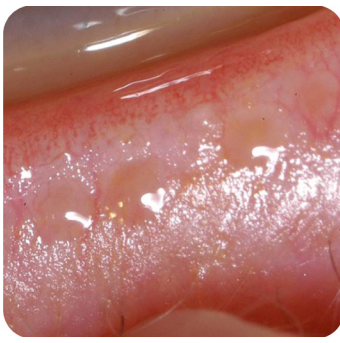
Taking a thorough history should sort out other important factors, as well. For instance, you must ask about risk factors such as systemic diseases, including allergy, rosacea and ocular diseases such as meibomian gland dysfunction (MGD) and blepharitis. Don't forget to inquire about any systemic medications such as antihistamines or preserved eye drops that the patient might be using. The patient's age and hormonal situation will have an impact on their ocular surface and potential dry eye symptoms, as well.

### ANTERIOR SEGMENT EXAMINATION

When performing the slit lamp exam, start from the outside working your way inwards. Look at the eyelids, lashes, and margins, and remember to flip the eyelids so that you can inspect the lower and upper conjunctiva. You won't



If you see or suspect a dry eye problem tell the patient; then set realistic postoperative expectations: under-promise so you can over-deliver



## LID MARGINS

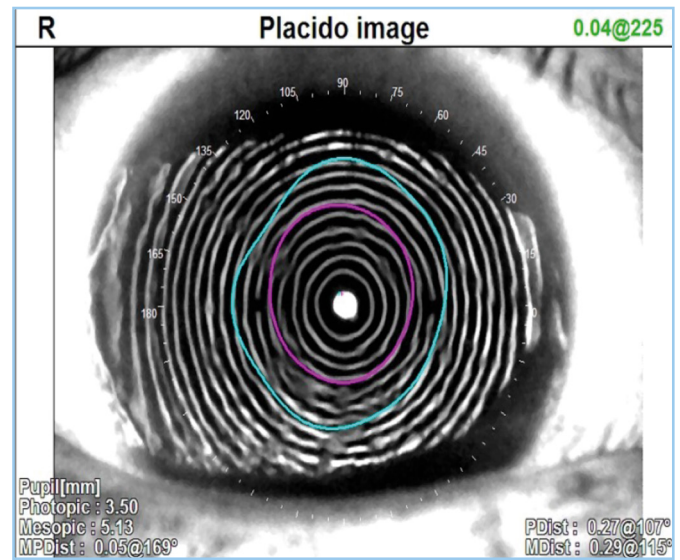
Figure 3: Test the function of the meibomian glands by pressing on the eyelid margins and evaluating the quality of secretions

often find pathology, such as superior limbic keratoconjunctivitis or cicatrising conjunctivitis; however, you must consider the possibility because the postoperative implications could be serious if these findings are overlooked. Make sure you look for the conjunctival folds, as well as at the tear film and meniscus. Don't forget to test the function of the meibomian glands by pressing on the eyelid margins, and judge the expressibility and quality of secretions. (Figure 3)

Two simple ways to evaluate the health of the ocular surface include staining and TBUT measurement, and both are accomplished with a drop of fluorescein. If the TBUT is below 10 seconds, that indicates tear film instability; if it is less than five seconds, that signifies dry eye. With respect to staining of the ocular surface, the fluorescein stains areas with disruption of the cell junctions and shows epithelial erosions. Any staining signifies an abnormality. When you are working with fluorescein, you should document the intensity and the distribution of the staining over the cornea, but you should also include the conjunctiva in the grading of staining.

The Tear Film and Ocular Surface Society's (TFOS) Dry Eye Workshop (DEWS) report recommends a non-invasive TBUT measurement method using Placido based topography. (Figure 4) It states that simply instilling a drop of fluorescein disturbs the breakup time. It is not obligatory to perform a non-invasive tear break-up time (NIBUT) measurement, but next time you do a topography, pay attention to inconsistencies between the eyes or changes in topography between blinks; check if there are disparities from visit to visit, as this can signify dry eye.

Schirmer testing can be helpful to differentiate aqueous deficient dry eye from evaporative dry eye disease. When I perform this test, I do so without anaesthesia to avoid false positive findings. If I have a value of less than 5mm



## TOPOGRAPHY

Figure 4: The Tear Film and Ocular Surface Society's (TFOS) Dry Eye Workshop (DEWS) report recommends a non-invasive TBUT measurement method using Placido based topography

after five minutes without anaesthesia, I can be certain that the patient has a problem of tear production.

In conclusion, if you find OSD or DED, start the patient on unpreserved artificial tears – or a more advanced regimen including anti-inflammatory drops or eyelid hygiene regimens. If necessary, schedule a follow-up visit, and perform your biometric measurements again when the patient returns. Most importantly, explain what OSD represents as far as its impact on postoperative outcomes, as well as the critical nature of treating it before cataract surgery.

*Carina Koppen MD, PhD is Professor of Ophthalmology, Department of Ophthalmology, Antwerp University Hospital, University of Antwerp, Antwerp, Belgium.*

*E-mail: carina.koppen@uza.be*

*Financial Disclosure: Santen, Théa, Zeiss, and Horus.*



## Expanding Understanding of OSD with New Diagnostic Tools

*By José M. Benítez-del-Castillo MD*

It is well known that dry eye and ocular surgery are related and that different types of surgery are associated with more or less dry eye. For instance, we know that if phacoemulsification is performed, the dry eye severity of a patient with pre-existing DED will increase by one level; whereas dry eye in patients who undergo LASIK increases by two levels.

There are many new and interesting tools available to diagnose and measure dry eye. For instance, the Oculus Keratograph 5M (Figure 5) is a corneal topography system that does everything a topography unit usually does, but it also has a built-in keratometer and a high-resolution colour

camera. Among its unique features is the ability to examine the meibomian glands and non-invasively measure tear film break-up time (TBUT); it also performs tear meniscus height measurement and evaluation of the lipid layer. The system shows if the ocular surface is normal or abnormal, and it also provides a way to track change over time. (Figure 6)

To appreciate the value of a keratometer or any tool that grades TBUT, it is important to understand how TBUT relates to dry eye. The blink spreads the tear, evenly redistributing the tear film over the ocular surface; the tear film breaks prior to resurfacing via blink; the ocular surface is left exposed to external insult; ocular discomfort occurs within one second



Figure 5: Non-Invasive TBUT

of tear film break-up; then a blink occurs and re-establishes the tear film. The brief period of exposure before each blink adds up over days, weeks, and years to a large amount of time during which the ocular surface is unprotected. Signs and symptoms of dry eye become more prevalent over time, which is why blinking frequency should be related to TBUT.

Tear osmolarity can be measured by a nano-osmolarimeter, such as Tearlab. This device provides an immediate result after automated collection of a few nanoliters. Values above 300mOsm/L and interocular variability of >8mOsm/L are considered abnormal. Another useful instrument is the I-PEN (I-Med Pharma), a small, hand-held, point-of-care, diagnostic device to detect and indirectly measure the tear film osmolarity levels. It takes less than five seconds per eye to perform this test with the I-PEN.

“ To appreciate the value of a keratometer or any tool that grades TBUT, it is important to understand how TBUT relates to dry eye

Confocal microscopy is useful in the evaluation of dry eye on several levels. We can study the ocular surface and the corneal epithelium, and we can also study the meibomian glands and identify patients with meibomian gland dysfunction (MGD). It is also extremely useful for imaging corneal nerves. The DEWS II definition of DED indicates that impaired nerve sensitivity is integral to DED. Along these lines we have the Cochet-Bonnet aesthesiometer, and I have a non-contact aesthesiometer – that is strictly for research; these devices test for corneal nerve sensitivity. In the future, we will need non-invasive instruments to perform this function in the office.

The Phenol Red Thread test (Ophthalmicdata) is an inexpensive way to test tear volume. It is similar to performing a Schirmer test but can be accomplished in 15 seconds. A novel way of testing tear volume is to measure lacrimal meniscus height with the SMTube (I-Med Pharma), a dry eye screening device that takes five seconds. A normal finding falls in the  $5.5 \pm 1.3\text{mm}$  range, whereas DED falls in the range of  $0.82 \pm 0.43\text{mm}$ .

A discussion of ways to evaluate the ocular surface and tear quality in surgical candidates would not be complete without mention of InflammDry (Quidel). This device is

a rapid result, in-office test that detects elevated levels of MMP-9, an inflammatory marker that is elevated in the tears of patients with dry eye disease.

Meibography, interferometry and tomography are also useful for evaluating the health of the ocular surface. Interferometers measure the thickness of the lipid layer of the tear film. The lipid layer of the tear film is decreased in patients with MGD, which is the most frequent cause of dry eye. Interferometry also diagnoses MGD by measuring the lipid layer of the tear film, but the LipiView interferometer also provides information about the quality of patient's blinking; for instance, partial blinks are not useful because they do not provide the same amount of protection to the ocular surface as complete blinks do.

Most of these high-tech devices have less costly, low-tech alternatives. For instance, instead of using InflammDry, you can perform a tear film clearance test by instilling a drop of fluorescein and seeing how long the dye resides on the ocular surface; instead of using LipiView, you can express the meibomian glands at the slit lamp; the use of cold light can be used to perform meiboscopy in place of meibography; and instead of employing an HD Analyser to perform the vision TBUT, we can rely on patient history and topography.

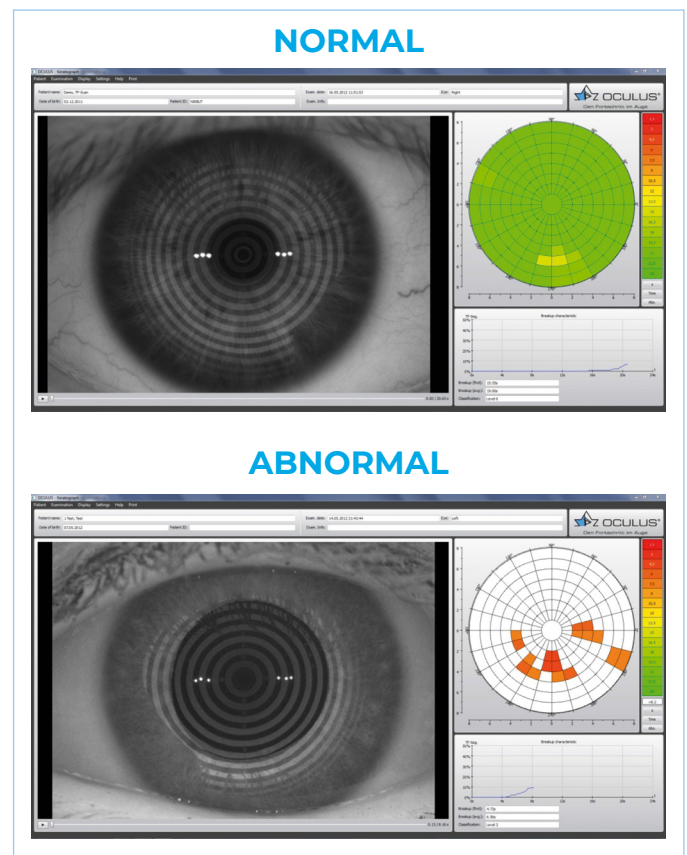


Figure 6: Non-Invasive TBUT

José M. Benítez-del-Castillo MD, PhD is professor and chairman of ophthalmology UCM, Hospital Clínico San Carlos, Clínica Rementería, Madrid, Spain.

E-mail: benitezcastillo@gmail.com

Financial Disclosure: Abbvie, Alcon, Allergan, Angelini, Bausch & Lomb, Brill, Dompé, Esteve, Novartis, Santen, Théa, Visufarma.



# Management of Ocular Surface in the Context of Surgery

By Jesper Hjortdal MD, PhD

**W**hen it comes to ocular surgery patients who have ocular surface disease (OSD), just a few minutes spent on education and treatment recommendations preoperatively can improve postop outcomes and patient satisfaction.

When diagnosing and treating dry eye disease (DED) in ocular surgery patients, consider the stages as explained by DEWS II:

**Stage I:** Requires only patient education, environmental modifications, modification of systemic medications, ocular lubricants and lid hygiene;

**Stage II:** Is helped by non-preserved lubricants, moisture goggles, punctal occlusion, meibomian gland expression, topical antibiotics/corticosteroids/cyclosporine/lifitegrast and oral antibiotics;

**Stage III:** Relies on a more intense regimen of oral secretagogues, serum eye drops, bandage contact lenses (CL) or rigid scleral lenses;

**Stage IV:** Suggests that longer duration topical steroids, amniotic membrane grafts, permanent punctal occlusion and other surgical approaches are in order.

In Europe, we often rely on fast-track clinics for refractive surgery and cataract surgery, so there's a focus on surgery, as opposed to chronic care. What's more, high-volume clinics rarely individualise care. Also, in Europe not all therapeutic options are at our disposal, as we do not have access to all the DEWS-recommended treatments. Most European countries have socialised medicine, so we are not reimbursed for advanced OSD treatments and patients are not accustomed to paying out of pocket – at least not in Denmark where I practice. On the other hand, all patients in Denmark have free access to modern cataract surgery.

## ENSURE THE BEST OUTCOME

That said, we need to do what we can to ensure the best possible outcome, and thus we must consider what category of OSD the patient falls in, improve the situation before surgery and reduce the risk of complications or dissatisfaction after surgery. When deciding on your plan, consider this decision tree: determine the severity of the OSD; consider the type of surgery – corneal refractive, cataract/IOL, corneal transplant/other; and finally decide what to do and when to do the surgery.

For instance, in a mild-to-moderate OSD case, you might see some staining and reduced tear break-up time. You can suggest the use of lubricants, perhaps cyclosporine or mild topical steroids. A punctal plug might help, as would lid hygiene, expression of meibomian gland secretions and a course of antibiotics.

When it comes to more severe cases with cicatricle changes of the conjunctiva – for instance, past Stevens-Johnson syndrome, or graft vs host disease after bone marrow transplantation – treatment would be more complex. In cases like that, we might use a type of scleral lens that can keep the cornea moist. In my experience that has been a game changer for many of my patients. It improves their life and makes them happy. In Denmark, we can also use allogenic serum eye drops for patients in this category; however, they are not available everywhere. Tarsorrhaphy is sometimes effective, and definitely useful if we have a patient with, for example, severe pemphigus. These patients also need to be immune-suppressed optimally in order to improve the eye as much as possible before surgery.

## Case Example (LASIK Surgery)

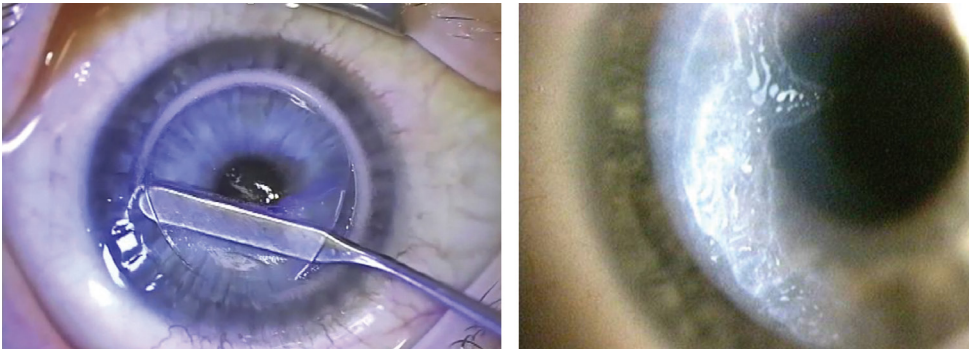


Figure 7: After you lift the flap in the case of a LASIK patient who has DED, you might find that there is a little dislocation of the flap edge and you can have epithelial ingrowth, which can really cause trouble

## Case Example (SMILE Surgery)

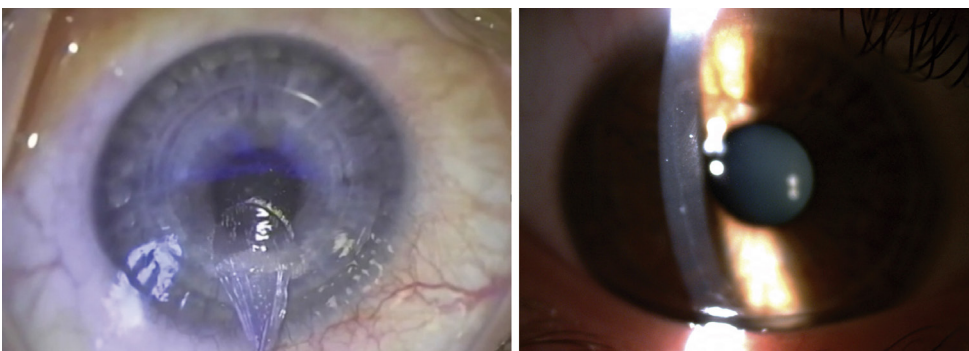


Figure 8: Another example where DED might be problematic is the case of a patient who is undergoing SMILE surgery. If, for instance, there is debris in the tear film, you can have difficulty cutting the lenticule, difficulty removing it, and it can culminate in a perforation of the anterior cap. Fortunately, in this case, this occurred outside of the optical axis and the patient did well

## Failure to access and identify tear film instability results in erroneous measurement of keratometry, topography, and refraction

In the most severe cases, we have to weigh the risks and benefits and sometimes conclude that surgery is not advisable. Alternatively, you might opt to delay the procedure until the patient becomes more stable in order to avoid serious complications or worsening of symptoms.

In the case of a LASIK patient who has DED, after you lift the flap you might find that there is a little dislocation of the flap edge and you can have epithelial ingrowth (Figure 7), which can really cause trouble.

Another example where DED might be problematic is the case of a patient who is undergoing small incision lenticule extraction (SMILE®) surgery. If, for instance, there is debris in the tear film, you can have difficulty cutting the lenticule, difficulty removing it, and it can culminate in a perforation of the anterior cap. Fortunately, in this case (Figure 8) this occurred outside of the optical axis and the patient did well.

### TEAR FILM STABILITY

It is always important to have a stable tear film, but it is critically important when the patient is getting a toric IOL or a multifocal IOL. We must optimise the ocular surface and tear film preoperatively in cases such as these, where biometric measurements and IOL power are tied to successful outcome.

In conclusion, I recommend more intense follow-up of surgery patients who have preoperative OSD. They can develop epithelial defects and if you treat them with steroids they can end up with a stromal ulcer. Finally, when implanting purely refractive IOLs, it is imperative to treat the OSD and then repeat the biometry before performing surgery; and be sure to explain to the patient what you are doing and why you are doing it.

*Jesper Hjortdal MD, PhD is a clinical professor in ophthalmology, Aarhus University, Denmark, and Medical Director of The Danish Cornea Bank.*

*E-mail: [jesper.hjortdal@dadlnet.dk](mailto:jesper.hjortdal@dadlnet.dk)*

*Financial disclosures: Zeiss.*

*Supported by an unrestricted educational grant from*



Supplement  
February 2019



ESCRS/  
EuCornea  
Education Forum