

Lisbon 2005

Anterior Segment imaging

Roibeard O'hEineachain in Lisbon

A BROAD range of new instruments for imaging the anterior segment are becoming available to ophthalmologists that may improve both the visual outcome and safety of cataract and refractive surgery, reported researchers at a symposium at the XXIII Congress of the ESCRS.

Dan Reinstein MD MA FRCS(C) commenced the session with a discussion on the many ways high frequency ultrasound can be applied in modern refractive surgery, whether it involves corneal laser ablation or phakic IOLs.

Dr Reinstein is the co-inventor of the Artemis II (Ultralink LLC), an arc-scanning VHF digital ultrasound scanning device. The machine enables the high-resolution scanning of the different layers of the cornea, and can also provide precise measurements of the other components of the anterior segment, such as the angle-to-angle diameter, the iris configuration and anatomy, and the sulcus-to-sulcus diameter in three dimensions, he said.

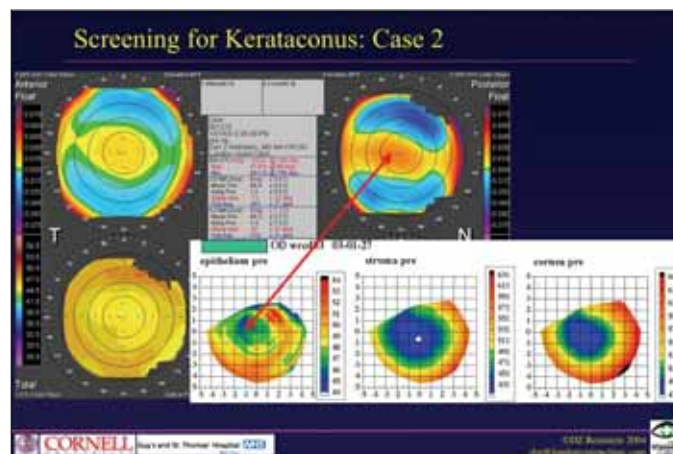
He and his associates at the London Vision Clinic currently use the Artemis on a routine basis to screen patients for keratoconus and other possible contraindications to procedures such as laser refractive surgery and to measure residual stromal depth in patients referred for LASIK re-treatment. They also use the instrument for determining the angle-to-angle and sulcus-to-sulcus diameters for the sizing of anterior and posterior chamber IOLs.

The Artemis II employs multi-meridian scanning to obtain three-dimensional data sets. Infrared eye position control enables the surgeon to know exactly from where on the eye or cornea a scan plane was taken. Three-dimensional data acquisition takes only three minutes per eye.

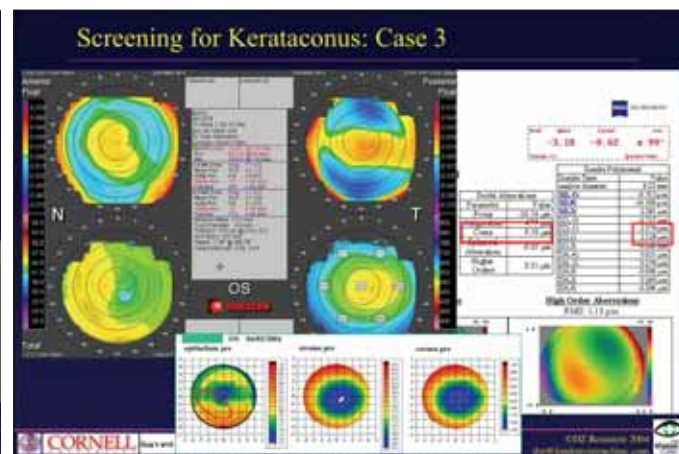
"The way that the Artemis becomes a refractive surgery instrument is by having simultaneous optical and ultrasound imaging so that any of the ultrasound biometry is correlated to an optically relevant position," he explained.

Screening for Keratoconus

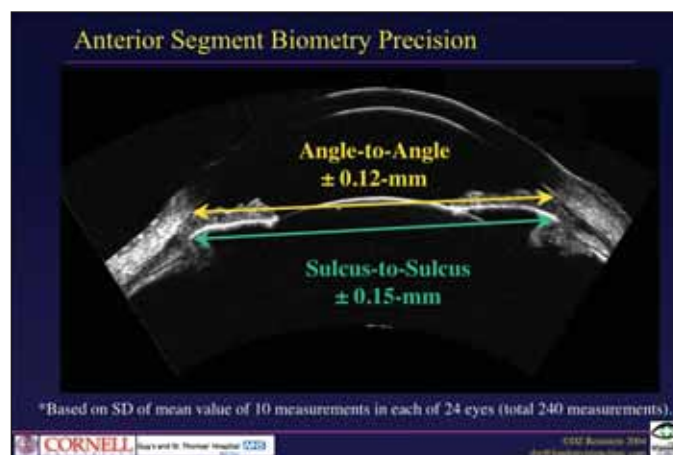
The instrument's published precision for localising surfaces within the cornea is less than 1.0 micron. This accuracy not only enables the identification of patients in whom corneal ablative procedures are contra-indicated, it can also identify patients



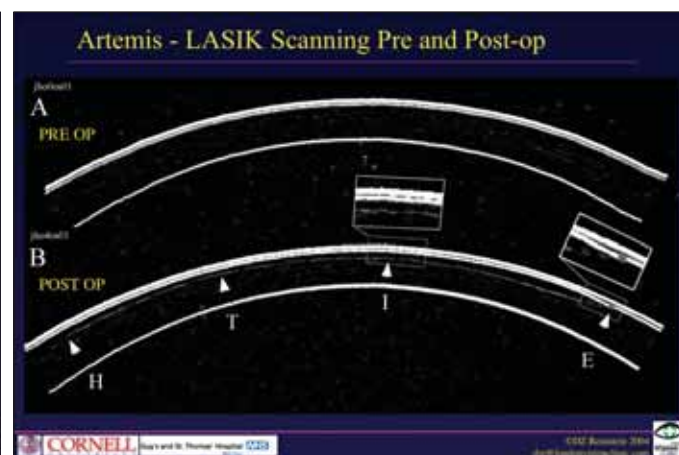Orbscan showing perfectly concentrically symmetrical front surface topography, and only slight temporal decentration of the posterior surface apex of the cornea. However, the epithelial thickness profile shows eccentric epithelial thinning co-incident with the back surface apex temporal displacement. This epithelial thinning is surrounded by thickening of the epithelium – this picture is highly suggestive of early keratoconus of the front surface that has not yet 'shown through' due to epithelial compensation.



Orbscan exam showing nasally displaced front surface apex on surface topography, and slightly temporally displaced back surface apex. The wavefront exam shows very high coma, and the higher order aberration plot shows an optical asymmetry consistent with keratoconus. The epithelial thickness profile of this eye however shows no epithelial thinning over the region of raised wavefront infero-nasally; this effectively excludes the presence of a 'cone' on the front surface of the cornea, and enables keratoconus to be confidently excluded despite the other soft-signs present.



Anterior segment B-scan by Artemis VHF digital ultrasound scanning technology showing very high resolution imaging extending behind the iris. The Artemis measurement precision is the highest available for angle-to-angle measurements (120-µm) or sulcus-to-sulcus measurements (150-µm).



Horizontal B-scan of a cornea before and after LASIK showing clear delineation of the flap interface from keratome entrance (E) to hinge (H), including micro-details such as incomplete apposition of Bowman's (image right magnification E) and small irregularities in the stromal cut (centre magnification - I)

who are suitable despite topography that would normally be interpreted as suggestive of keratoconus.

Dr Reinstein noted that his studies have shown that the Artemis II can identify a cardinal feature of early keratoconus, even before it is detectable by surface topography. Namely, a back surface asymmetry accompanied by a thinning of the epithelium over the incipient anterior stromal cone and a thickening of the epithelium peripheral to this cone.

"There will be invagination of the epithelium by the anterior surface cone, thus masking the stromal surface bulging in the early stages. Eventually the epithelial surface begins to bulge also, and that is when such a keratoconic cornea becomes detectable by

surface topography," he explained.

On the other hand, back surface asymmetries in the absence of an irregular epithelium is unlikely to be indicative of early keratoconus, he pointed out.

Dr Reinstein described the case of an 18-year-old woman who wished to undergo LASIK. She had -3.25 D sphere in both eyes and -0.25 D of cylinder in one eye. The keratometry and corneal thickness measurements were unremarkable in both eyes. However, when he looked at her eyes with the Artemis he found that there was a thinning of the epithelium corresponding to a displaced back surface apex, which totally masked the projection of the anterior stromal surface.

"You would have done LASIK in this patient if you hadn't seen the epithelial thickness profile in conjunction with the very mildly displaced back surface apex because there would have been no reason not to."

In another case, Artemis findings were able to determine that a potentially suspect case of keratoconus was actually a safe candidate for LASIK. The patient was 33-year-old woman with -4.75 D sphere 0.75 D cylinder in one eye and -4.00 D sphere and -0.50 D cylinder in the other.

The front surface of one of the patient's eyes had an unusual topography and there was a displaced back surface with inferior steepening. Moreover, aberrometry showed she had 2.2 microns of coma. She also had a brother with keratoconus.



Dan Z Reinstein

Dan Z Reinstein, MD MA FRCS(C)
Medical Director,
London Vision Clinic,
London, UK
dzr@londonvisionclinic.com



Joaquim Neto Murta

Joaquim Neto Murta MD, PhD
Department of Ophthalmology
Coimbra University Hospital,
Coimbra, Portugal
jmurta@netcabo.pt



Jack Holladay

Jack T. Holladay, MD, MSEE, FACS
Clinical Professor of
Ophthalmology
Baylor College of Medicine
Houston, Texas, USA
holladay@docholladay.com



Julián García-Feijoo

Julián García-Feijoo MD PhD
Profesor Titular de Oftalmología
Instituto Ramon Castroviejo,
Universidad Complutense,
Hospital Clinico San Carlos,
Madrid, Spain
mherrerad@sego.es



Georges Baikoff

Georges Baikoff MD,
Clinique Monticelli,
Marseille, France,
g.baik.opht@wanadoo.fr



Marie-José Tassignon

Marie-José Tassignon MD PhD,
University Hospital Antwerp,
Antwerp, Belgium
marie-jose.tassignon@uza.be

"Normally I would not have done surgery on this patient but I did an Artemis scan and found that the epithelial thickness profile had no correlation with the optical bump being caused by a cone on the stromal surface. What this means is that there is no cone on the anterior surface of the cornea and therefore I can confidently tell you that this is not a case of keratoconus despite this coma. Many cases that are deemed good candidates for wavefront guided treatment because they have coma must first be excluded from having keratoconus: epithelial thickness mapping allows this exclusion to be made."

Phakic IOLs

VHF digital ultrasound can also be useful for screening patients for iris abnormalities that might contra-indicate implantation of an Artisan/Verisyse (Ophtec/AMO) lens, Dr Reinstein noted. Implantation of the lenses in eyes with irides that have irregular thickness profiles can give rise to excess compression of the iris pigment epithelium onto the crystalline lens, which can in turn give rise to posterior synechiae.

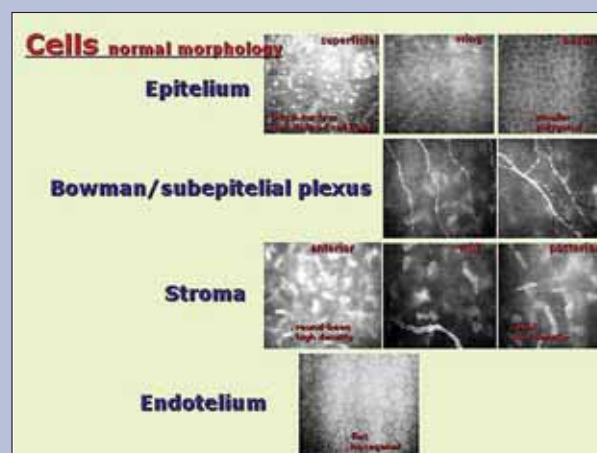
VHF digital ultrasound can also provide very accurate measurement of iridocorneal angle diameters for sizing angle-supported phakic IOLs, and sulcus diameters for sizing ICLs. Studies with VHF digital ultrasound technology suggest that ICL sizing estimations based on white-to-white are of no value, he added.

He noted that in a study involving 10 myopic and 10 hyperopic patients in whom he and his associates determined intraocular ocular dimensions using the VHF digital ultrasound technology and white-to-white by digital photography, there was no statistical correlation between white-white and sulcus-to-sulcus for myopes or hyperopes. Similarly, there was no correlation between white-to-white and angle-to-angle for myopes, although there was a weak correlation in hyperopes.

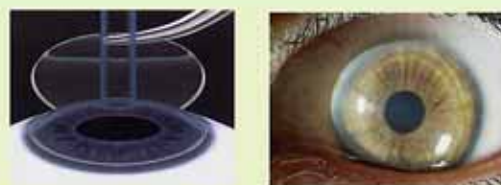
"This is highly significant - because it means that the current method of actually basing the ICL size on the white-to-white measurement will give worse results than ignoring the white-to-white completely and using a one-size-fits all. And while there was a correlation in hyperopes, you have to remember that hyperopes are the least likely candidates for angle-supported IOLs."

Confocal Microscopy

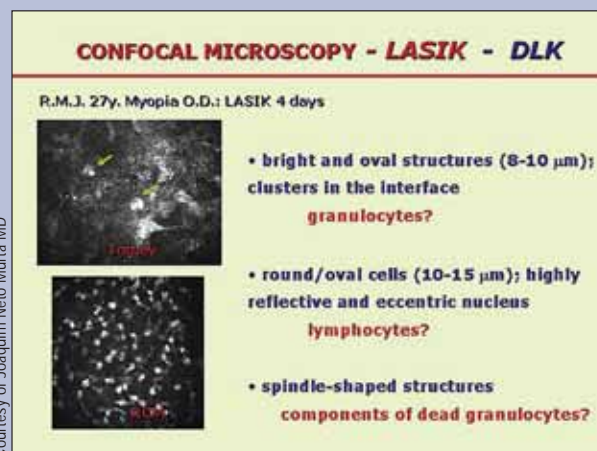
Joaquim Neto Murta MD PhD, Coimbra, Portugal, followed with a description of the many potential applications of confocal microscopy in corneal surgery.



Confocal microscopy is a useful technique for *in vivo* evaluation after LASIK because it is able to show cellular modifications inside the corneal layers



LASIK - Most effective treatment in low to moderate myopia



Courtesy of Joaquim Neto Murta MD

Confocal microscopy is an optical sectioning technique producing images free from out-of-focus blur. It is a light microscopy technique and commonly employs visible wavelength lasers as light sources and confocal apertures or 'pinholes' in the detection path.

Its principal advantages over conventional biomicroscopy include a very high spatial resolution, its ability to generate completely in-focus 3D images of microscope samples and reduced sample preparation in histological studies. Furthermore, when used as an *in vivo* technique it provides high contrast imaging of all layers of the cornea as well as the tear film, limbus, and conjunctiva.

"For these reasons *in vivo* confocal microscopy is a useful tool to study cystic diseases, dystrophies, microorganisms deposits as well as the post-operative aspects of corneal procedures such as, LASIK, LASEK, PRK, DLEK, keratoplasty procedures, intracorneal rings implantation, etc."

Dr Murta and his associates in Coimbra currently use two different confocal microscopy instruments: the Confoscan P4 (Tomey) and, more recently, the Heidelberg Retina Tomograph (Rostock module HRT II + RCM). Of the two devices, the HRT II+RCM has the highest spatial resolution and magnifying power, he said.

Corneal cell morphology

Confocal biomicroscopy can provide sharp images of corneal cell morphology of each layer of the cornea, Dr Murta noted. In the epithelium it enables the clear visualisation of the cells

of superficial layers with their bright nuclei and well-defined cell body, the intermediate wing cells of the internal epithelial layers, and the smaller polygonal basal cells.

In the stroma, it reveals the decreasing density of cells towards the posterior cornea as well as the nerve fibres belonging to the deep corneal plexus. In the endothelium it provides well-defined images of the tissue's flat hexagonal cells.

Corneal surgery

After LASIK procedures, the technology therefore allows the physician to accurately assess stromal keratocyte density and activity, haze, flap thickness, re-innervation, microfolds at the Bowman's layer, and particles at the interface level.

"Confocal microscopy is a useful technique for *in vivo* evaluation after LASIK because it is able to show cellular modifications inside the corneal layers. It provides us with a better understanding of interface problems, wound healing and flap morphology."

Studies undertaken with confocal microscopy have provided new insights into the aetiology and pathology of interface particles, which are present in the early postoperative months in eyes that have undergone LASIK.

The technique provides clear images of the highly reflective particles which may represent metallic particles from the blade, powder from gloves, epithelial remnants and low reflective particles, which decrease with time and stabilise at six months and may represent cell degeneration products or inflammatory cells. Confocal microscopy studies indicate that particle density does not correlate with flap thickness, haze intensity or ablation depth, he noted.

In cases of post-LASIK diffuse lamellar keratitis, confocal microscopy reveals such features as bright and oval structures, possibly granulocytes, 8-10 microns in diameter, clustering in the interface. It also reveals round cells 10-15 microns in diameter with highly reflective and eccentric nuclei, which are possibly lymphocytes, and spindle-shaped structures, which may be components of dead granulocytes.

Confocal microscopy can also be used in the evaluation of the cornea following penetrating keratoplasty procedures. The images it provides can show early signs of

graft rejection or decompensation and the status of corneal re-innervation. It also allows visualization of structural abnormalities within the stroma, including scarring, and post-inflammatory and trophic phenomena even in the absence of any clinical complications.

"The modern implementation of this technology has transformed the confocal microscopy into a powerful diagnostic tool," he stressed.

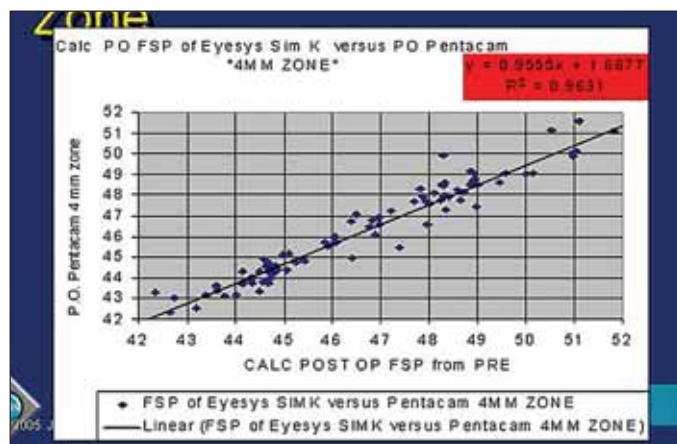
Scheimpflug Imaging

Jack Holladay MD, MSEE, FACS, Houston, Texas, told the symposium that new Scheimpflug tomography devices such as the Pentacam (Oculus) would be in increasing demand as patients who have undergone corneal refractive surgery reach the age when they will require cataract surgery.

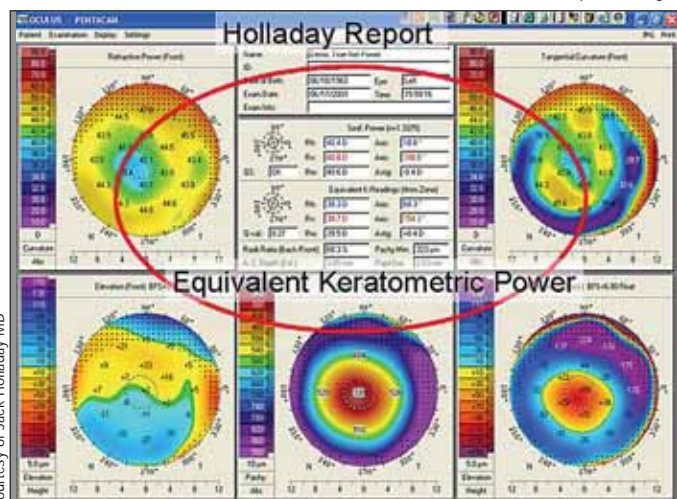
"IOL power calculations after refractive surgery are especially difficult because the corneal power can no longer be measured accurately with current instruments, and eyes that have undergone such procedures are certain to have been ametropic before refractive surgery, making the dimensions of the eye much more likely to be unusual," he said.

He noted that there are two factors that make corneal measurements with current keratometers and topographers unreliable for IOL calculations in eyes that have undergone previous refractive surgery. The first is that the instruments take measurements paracentrally and extrapolate the cornea's central power.

"The measurements do not reflect the actual central power of the cornea, the keratometer does not measure the central 3.2 mm of the cornea and topographers miss about the central 1.2-1.6 mm, depending on the specific instrument. And this is the actual region we need to know."



In a study involving 100 eyes before and after LASIK, postoperative measurements with the Pentacam were within 0.5 D of the estimated net corneal power change.



The Pentacam's software provides a "Holladay Report", which is the Pentacam-corrected equivalent of the conventional back-surface-adjusted keratometry reading.

The second factor is that the instruments do not measure the back surface of the cornea. Most of the current IOL power calculation formulas are based on the assumption that the back surface of the cornea has a radius of curvature that is 82.2% of that of the front curvature. However, after corneal refractive surgery the ratio between the curvatures of front and back corneal surfaces becomes altered.

There are several current methods for estimating the true corneal power in such eyes. They include historical approaches, which compare preoperative keratometry readings with the change in refraction from surgery, and those that involve the use of rigid contact lenses.

"Each of these methods has problems, in that the refractive change that is measured may be partly a result of refractive changes in the cataract. The contact lens method requires the patient to have moderately good vision and assumes the back corneal radius is 82% of the front radius."

Pentacam overcomes shortcomings of keratometry and topography

Unlike current keratometers and topographers, the Pentacam measures both the central cornea and the corneal back surface, Dr Holladay noted. The instrument has a camera in the periphery and a slit-beam in the centre and rotates 360 degrees taking 50 sample meridians. The device also corrects for the eye movement that occurs during fixation and re-registers the centre point in all 50 sections.

To validate the accuracy of the Pentacam's measurements, Dr Holladay and his associates conducted a study involving 100 eyes before and three months after LASIK or PRK. The patients in the study ranged in age from 20 to 45 years and were therefore unlikely to have had refractive changes in their crystalline lens from cataract changes.

They found that preoperative measurements with the device had a 99% correlation coefficient with those of the Eyesys and Humphrey topographers. Furthermore, postoperative measurements were within 0.5 D on average of the net corneal power change estimated from preoperative measurements minus the surgically induced refractive change.

To add further ease-of-use to the Pentacam, the instrument's software provides a "Holladay Report", which is the equivalent of what the back-surface-adjusted keratometry reading would have been in an untreated eye with the net corneal power determined by the Pentacam. As a result, surgeons using the device do not need to change or adjust their

IOL power calculation formulas or A-constants for each IOL.

"With the Pentacam, I think we've now moved forward to a point that we'll now be able to directly measure the net corneal power in patients who have undergone refractive surgery without reference to preoperative data and have results that will get us within 0.5 D of our target."

Ultrasound Biomicroscopy

Julián García-Feijoo MD PhD Madrid, Spain, described how ultrasound biomicroscopy might be useful in the pre- and postoperative assessment of patients undergoing implantation of phakic IOLs.

UBM is a high-resolution technique that allows for the examination of the anterior and posterior chamber and peripheral retina. The resolution and technical characteristics of the currently available UBM instruments make them particularly valuable in the analysis of the anatomic relationships between different models of anterior chamber IOLs and adjacent intraocular structures, he said.

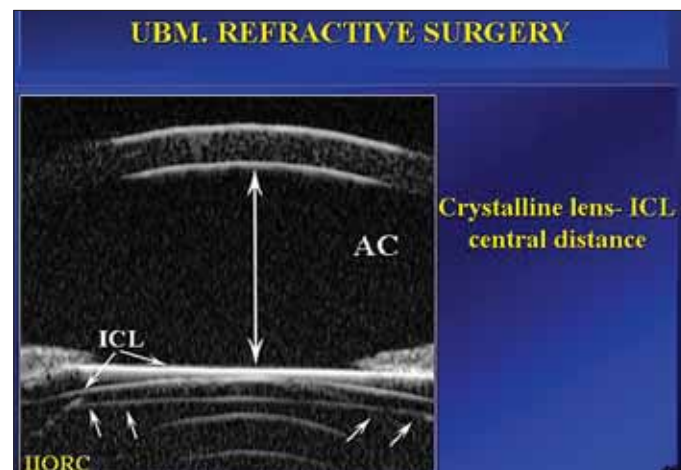
However, Dr García-Feijoo said that with UBM a compromise is sometimes necessary between image quality and the amount of area scanned. Currently available UBM instruments have transducers with frequencies of 50, 20 and 35 MHz. While the 50 Mhz transducer provides the best image quality and resolution, its scan field is limited to a 5x5 mm square. The 20 and 35 MHz transducers can produce images of the entire anterior or posterior chamber with a single scan.

"This is an important restriction when we want to examine the internal ocular diameters of the anterior and posterior chamber. It is therefore very important to optimise the transducer used to the purpose of your investigation."

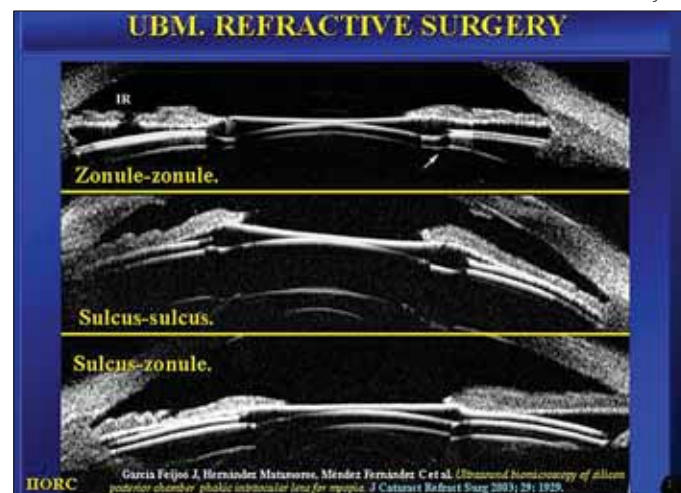
ICLs and PRLs behaviour in the eye

To illustrate the potential of UBM, Dr García-Feijoo presented a study that he and his associates conducted in 10 eyes of 20 patients implanted with ICLs to analyse and elucidate the in vivo position of the ICL and its relationships to the iris and crystalline lens.

They found that the distance between the ICL and the crystalline lens was different at the different radii of the ICLs and that the distances changed over time. In addition they found iris-ICL contact in all the cases and ICL-crystalline lens contact in 13 eyes and central contact in three eyes. Furthermore ICL rotation was evident in two eyes.



UBM findings showed iris-ICL contact in all the cases and ICL-crystalline lens contact in 13 eyes and central contact in three eyes.



PRLs appear to adopt three positions: the "ideal position" with both haptics on the zonule, the sulcus position with both haptics in the ciliary sulcus, and mixed positions.

In another two studies, in which they used UBM to analyse eyes implanted with PRLs, they detected iris-PRL contact in all the cases and PRL rotation in three of 11 hypermetropic eyes (27.2%), and in five of 16 myopic eyes (31.25%).

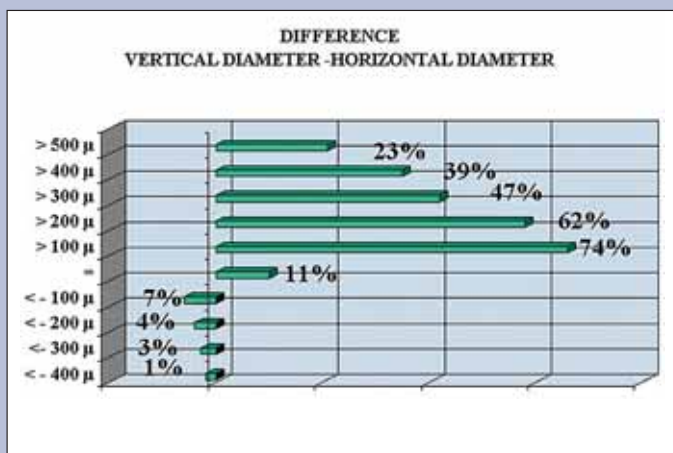
In addition, their findings indicated that PRLs could adopt three positions: the "ideal position" with both haptics on the zonule, the sulcus position with both haptics in the ciliary sulcus, and mixed positions. The adoption of one of these positions is probably related to the difference between the PRL diameter and the real diameter of the sulcus, he said, adding:

"Probably all these facts indicate that the lens must be better adjusted to the real anatomy of the posterior chamber. This is also important in the case of toric posterior chamber IOLs, if we just implant relatively oversized lenses, rotation could be prevented, but this might have complications in the long term, which are important, as these PCP-IOLs are usually implanted in young patients."

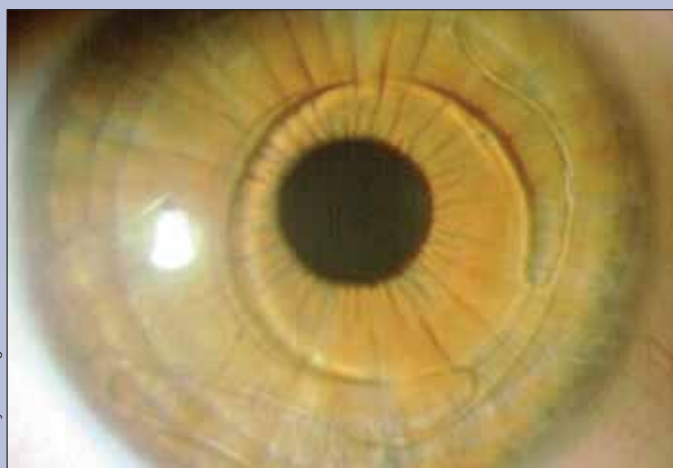Anterior Chamber OCT

Georges Baikoff MD, Marseille, France, reported that OCT of the anterior segment using the Visante™ (Carl Zeiss Meditec) has numerous applications in cataract, refractive and glaucoma surgery and may increase the long-term safety of phakic IOLs.

The Visante OCT is a non-contact device that can dynamically scan 360 degrees of the anterior segment. It has a range of potential uses including the evaluation of accommodation, measuring the angle in glaucoma patients, measuring flap depths and residual stromal thickness in LASIK patients who are candidates for re-treatment, and as a tool to measure intraocular dimensions prior to phakic IOL implantation.



Studies with the Visante have revealed that the vertical diameter of the anterior chamber is greater than the horizontal diameter.



It is necessary to match the IOL's diameter with the larger axis of the anterior chamber in order to avoid rotation of the lens and possible chafing of the endothelium.

"The new program developed for the cornea is going to be very important for the pre-operative evaluation of LASIK enhancements for patients having undergone LASIK surgery. Indeed, it is possible to obtain a pachymetric map of the cornea as well as establish a mean flap and stromal bed thickness map," he added.

Sizing phakic IOLs and patient selection

Two other important applications that the Visante OCT device will have in refractive surgery is the correct sizing of angle-supported phakic IOLs and the improvement of the selection criteria for implanting iris-fixated IOLs.

"Just as we explore the cornea for refractive surgery it is now also mandatory to explore different parameters of the anterior chamber before introducing a foreign body like phakic IOLs," Dr Baikoff added.

In the case of angle-supported phakic IOLs, studies with the Visante have revealed that the vertical diameter of the anterior chamber is greater than the horizontal diameter. It is therefore necessary to match the IOL's diameter with the larger axis of the anterior chamber in order to avoid rotation of the lens and possible chafing of the endothelium.

Commenting on iris fixated IOLs, Dr Baikoff noted that his anterior segment OCT studies have shown that there is a phenomenon in the ageing eye, which he calls the "crystalline lens rise", whereby the crystalline lens rises towards the iris over time. If an iris-fixated IOL is present and there is excessive crystalline lens rise, the iris can become squeezed between the two lenses resulting in pigment dispersion.

"It is when the "crystalline lens height" reaches the height of 600microns measured

from the base line which joins angle recess to angle recess, that pigment dispersion syndrome appears with Artisan implants."

Dr Baikoff has determined that if an eye has a crystalline lens rise of less than 600 microns and an anterior chamber depth greater than 3.2 mm there is no risk of pigment dispersion. However, in eyes with 400 microns of crystalline lens rise, Dr Baikoff advises patients that they may need to have their implant removed in a decade or so.

"In our anterior segment practice Visante anterior chamber AC OCT has become as necessary as topography is for corneal surgery."

Imaging the aberrations

Marie-José Tassignon, MD PhD, Antwerp, Belgium concluded the symposium with a discussion on the use

of aberrometry as a diagnostic tool to assess the reasons for visual complaints in unhappy patients.

Dr Tassignon noted that while aberrometry does not provide direct imaging of the eye it does provide a picture of the eye's optical quality. However, she emphasised that it should be used as a complementary measurement in conjunction with measurements of the axial length and the curvatures of the cornea and crystalline lens.

She pointed out that aberrometry on its own cannot determine which component of the optical system gives rise to any particular refractive error. She noted, for example, that a refractive myopia patient can have the same wavefront pattern as a patient with axial hyperopia.

Nonetheless, aberrometry can provide a clinician with a considerable amount of information about the optical quality of the eye. The technique provides an objective means of analysing the optical origin of a patient's complaints after both cataract and refractive surgery.

She noted, for example, that aberrometry was instrumental in the development of modern aspheric IOLs. Aberrometry, in conjunction with topography and other techniques demonstrated the need for lenses that compensate for the positive spherical aberration of the cornea, instead of adding to it as conventional spherical IOLs do.

Aberrometry also provides an objective evaluation of the visual complaints of patients with displaced lenses. Dr Tassignon cited the case of a patient who was unhappy following implantation of a ReStor multifocal IOL. Aberrometry not only determined that IOL tilting was the source of the complaint but also showed the undesirable Fresnel effects of the tilted lens.

Capsular bag healing

Aberrometry can also provide insight into the behaviour of the capsular bag and its influence on the final position of the lens in the eye, Dr Tassignon said.

"The capsular bag healing process can bring about hyperopic and myopic shifts and tilting of the lens. The wavefront-based impact these changes will have on the quality of vision is quite impressive."

Furthermore, aberrometry shows that performing nd:YAG laser capsulotomy does much more than just free the optical axis of the eye; it changes both the refraction and the higher order aberrations.

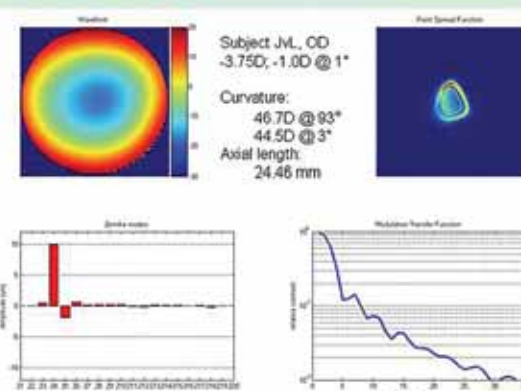
"This means that by freeing the optical axis you are also changing the position of the IOL within the capsular bag, which in some cases may benefit patients, and in other cases probably not."

In eyes treated with radial keratotomy, aberrometry will show a banding pattern on the wavefront, with each band corresponding to an RK incision. In LASIK-treated eyes, aberrometry will show a typical aberrational pattern arising from the flap hinge. However aberrometry cannot detect central islands.

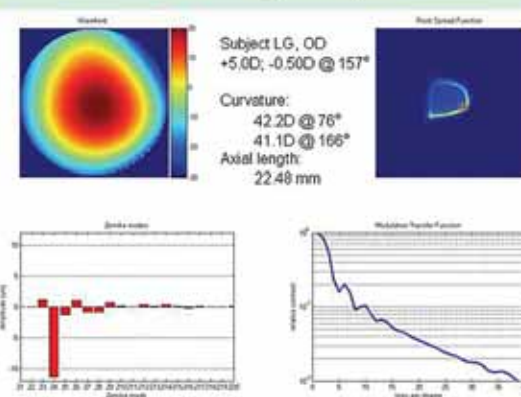
Dr Tassignon noted that different aberrometers will give different readings in the same eye and this is mainly due to each machine's individual technical specifications. The instruments differ in the number of samples they take and in their scan geometry, which can be polar, hexagonal, or Cartesian. In addition, the ease with which fixation targets are recognised by patients differs between machines.

"All these factors will influence your final result so before you link the aberrometer to a surgical procedure it is important to remember that an aberrometer

Refractive myopia

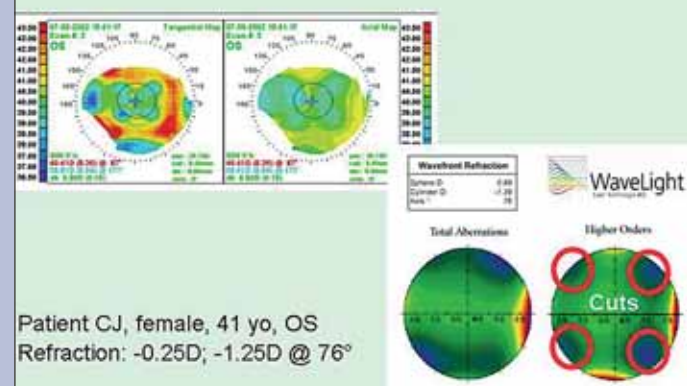


Axial hyperopia



A refractive myopia patient can have same wavefront pattern as a patient with axial hyperopia.

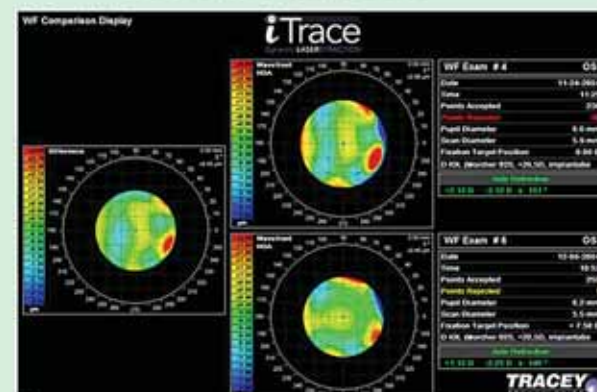After Radial Keratotomy



In eyes treated with radial keratotomy, aberrometry will show a banding pattern on the wavefront, with each band corresponding to an RK incision.

Treating PCO: YAG capsulotomy

Wavefront difference



Aberrometry shows that performing nd:YAG laser capsulotomy not only frees the optical axis of the eye; it changes both the refraction and the higher order aberrations.

is a measuring device that, like any other device, produces errors in its results." ■