



Manfred Tetz

John R Kearney

Canaloplasty procedure offers fresh hope for glaucoma patients

Dermot McGrath
in London

THE dilation and tensioning of Schlemm's canal may be an effective non-penetrating surgical method for the treatment of open-angle glaucoma, according to a number of investigators.

Presenting six-month data from a European prospective multicentre trial, Dr Manfred Tetz MD told delegates attending the XXIV Congress of the ESCRS that the approach known as canaloplasty seems to be a safe and effective means of lowering intraocular pressure (IOP) in patients with primary open-angle glaucoma (POAG).

"Our interim data showed that patients had a pre-operative IOP of 21.9 mmHg and used an average of two medications. At the six-month follow-up mark, mean IOP decreased 37 per cent to 13.8 mmHg," said Dr Tetz, Eye Centre Spreebogen, Berlin, Germany.

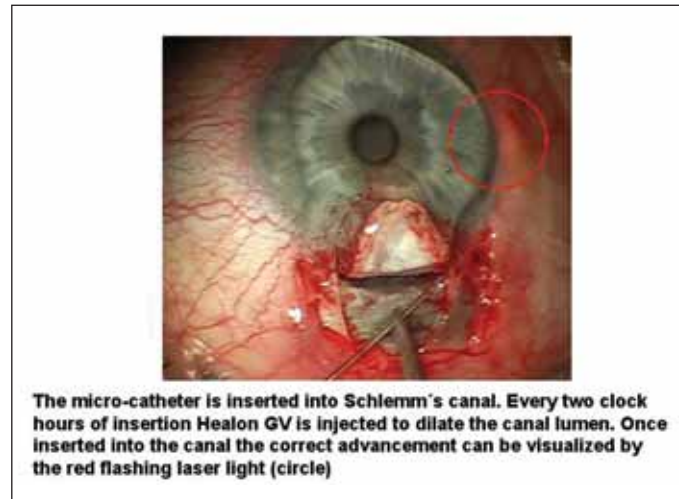
"Our interim data showed that patients had a pre-operative IOP of 21.9 mmHg and used an average of two medications. At the six-month follow-up mark, mean IOP decreased 37 per cent to 13.8 mmHg"

Manfred Tetz MD

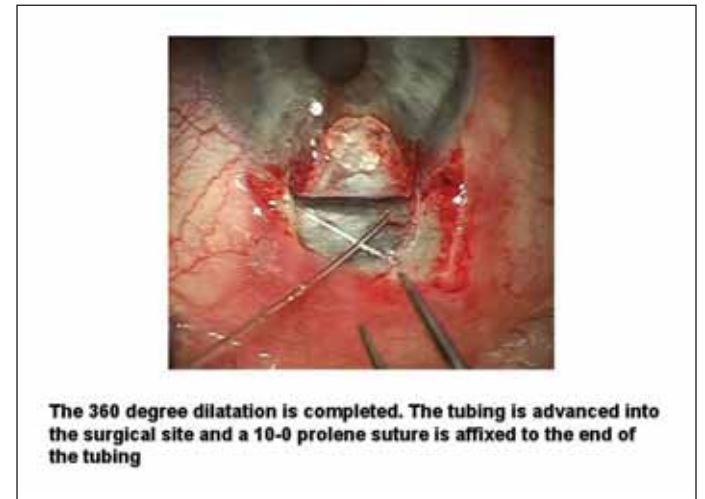
In Dr Tetz's study, the patients were examined postoperatively to evaluate the anterior segment and IOP. Several patients were also examined by high-resolution ultrasound imaging of the anterior segment angle to evaluate Schlemm's canal morphology. Ultrasound imaging showed how the tensioning suture successfully distended the inner wall of Schlemm's canal and the associated trabecular meshwork. The suture was also observed to maintain the canal lumen postoperatively.

Interestingly, Dr Tetz noted that of his own first 20 patients, (nine of whom underwent canaloplasty in combination with cataract surgery) the mean IOP at six months was 13.7 mmHg with a standard deviation of four.

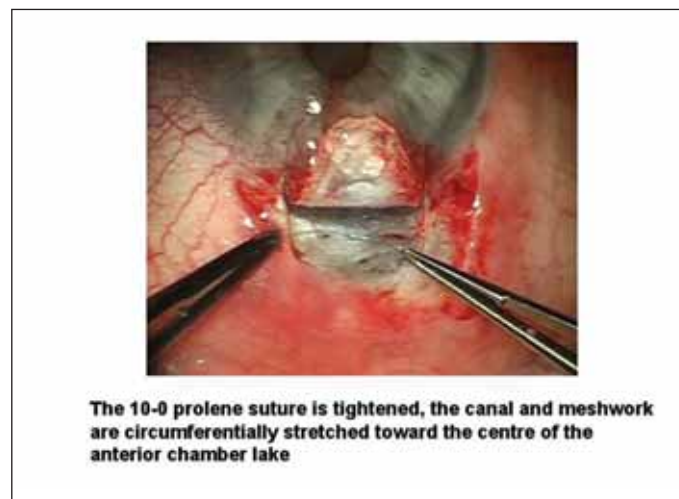
"Comparing this to our previous viscocanalostomy data, we were about 3 mmHg on average lower; and the drop actually increased from our average 30 per cent to 45 per cent using canaloplasty," he said.



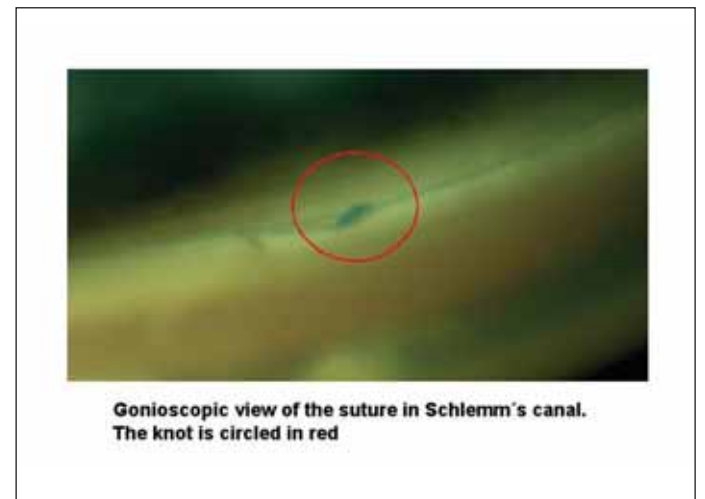
The micro-catheter is inserted into Schlemm's canal. Every two clock hours of insertion Healon GV is injected to dilate the canal lumen. Once inserted into the canal the correct advancement can be visualized by the red flashing laser light (circle)



The 360 degree dilatation is completed. The tubing is advanced into the surgical site and a 10-0 prolene suture is affixed to the end of the tubing



The 10-0 prolene suture is tightened, the canal and meshwork are circumferentially stretched toward the centre of the anterior chamber lake



Gonioscopic view of the suture in Schlemm's canal. The knot is circled in red

Dr Tetz also presented interim data from the ongoing European and United States canaloplasty multicentre study, which has now enrolled 244 patients. Of 188 eyes in that study that had not undergone previous glaucoma surgery, he noted that 89.4 per cent were successfully catheterised.

Learning curve

"There is a learning curve with this technique. If we remove the first 10 cases for each surgeon, we see that 100 per cent of eyes were successfully treated," he said.

To date, Dr Tetz said that there have been only five serious adverse events associated with the surgery. Two of these included respiratory/cardiac problems, as well as two single episodes of elevated IOP and one case of a continuous IOP elevation, which is still under investigation.

Dr Tetz stressed that while much longer follow-up was needed to fully assess the safety and efficacy of the canaloplasty procedure, the results thus far provide good grounds for optimism.

"While the study is ongoing we see that there is a success rate which is higher than

viscocanalostomy and we seem to have an improved intraocular pressure in the low to mid teens that is closer to normal episcleral venous pressure with a low overall complication rate," he said.

"While the study is ongoing we see that there is a success rate which is higher than viscocanalostomy and we seem to have an improved intraocular pressure in the low to mid teens that is closer to normal episcleral venous pressure with a low overall complication rate"

Manfred Tetz MD

From viscocanalostomy to canaloplasty

In an overview of the history and evolution of the procedure, John R Kearney MD explained that canaloplasty is essentially a non-penetrating approach to glaucoma surgery that utilises circumferential flow of the canal of

Schlemm into the outflow system. "The purpose of canaloplasty is restoring aqueous flow internally, thereby reducing the IOP to near episcleral venous pressure," he said.

Dr Kearney explained how canaloplasty evolved from the viscocanalostomy procedure pioneered by Robert Stegmann MD of Pretoria, South Africa. During initial trials of a flexible microcannula to dilate 360° of Schlemm's canal, Dr Kearney introduced the dilation procedure to Dr Stegmann, who in turn added the placement of an intracanalicular tension

Courtesy of Manfred Tetz MD

suture, creating the canaloplasty procedure. In effect, the difference between a viscocanalostomy and a canaloplasty is that the canaloplasty aims at opening the entire length of the canal, not just one section of it.

As in viscocanalostomy, the first step is the creation of parabolic superficial and deep scleral flaps to gain access into Schlemm's canal. The deep flap is dissected to the plane of Schlemm's canal and the sides of the deep flap are then dissected forward into the cornea. A flexible fibre-optic microcannula (iScience Surgical Inc., California) is then introduced into Schlemm's canal in order to perform viscodilation of the canal and associated collector channels.

The microcannula has a diameter of 200 microns and is equipped with an infrared beam at the catheter's tip to enable the surgeon to identify the precise location of the instrument as it passes through the canal.

No blebs, less complications

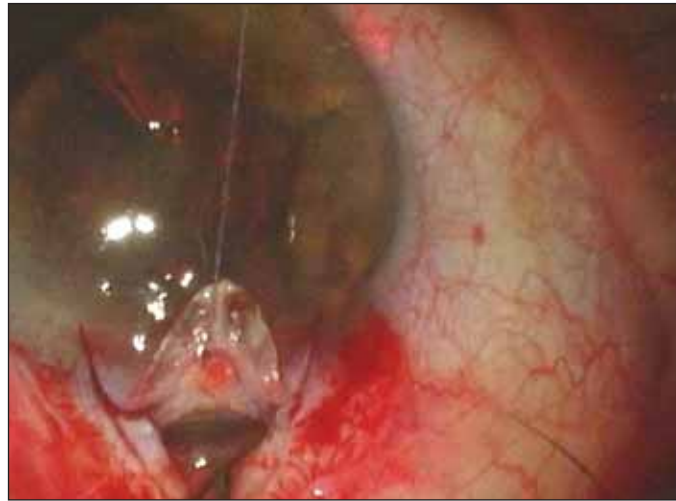After 360 degrees of canal cannulation, the microcannula is then used to insert a 10-0 prolene suture into the entire circumference of the canal and the ends are tied together to provide tension to the inner wall of the canal and the associated trabecular meshwork. Finally, the flap is tied tightly to avoid bleb formation, thereby reducing the long-term risk of infection, irritation or wound leak.

“With the canaloplasty procedure we are able to viscodilate and place the tension suture cinching it into the Schlemm's canal, confirming its position with proper tensioning and ultrasonic imaging and lowering the IOP levels to that achieved with trabeculectomy with mitomycin C”

John R Kearney MD

“The suture is tied to the end of the catheter which is withdrawn from the canal. Once the suture is tied, the tension stretches the trabecular meshwork facilitating better outflow into the canal, keeping the canal open and preventing its collapse, and disallowing the blockage of these drainage vessels from Schlemm's canal. So we end up with better flow into, within and out of the canal,” said Dr Kearney, founder and director of The Cataract Care Center, New York.

He added that using a new high-resolution ultrasound system, also designed by iScience, provides accurate



The micro catheter in Schlemm's canal via the surgical ostia and advanced about 120 degrees

localisation of Schlemm's canal and enables surgeons not only to see the effect of their surgery on ocular structures, but also whether or not the technique is producing the desired effect after surgery.

Reviewing the results to date, Dr Kearney said that the microcatheterisation of Schlemm's canal is a viable and repeatable procedure and assists in complete viscodilation of the canal,

“With the canaloplasty procedure we are able to viscodilate and place the tension suture cinching it into the Schlemm's canal, confirming its position with proper tensioning and ultrasonic imaging and lowering the IOP levels to that achieved with trabeculectomy with mitomycin C,” he said.

Retreatments viable for viscocanalostomy patients

For patients who have already undergone previous viscocanalostomy surgery, retreatment can be readily performed by dissection of the original scleral flap, exposing the previous aqueous flow paths for repair, according to Kurt-Dietrich von Wolff MD, FRCO.

“Newly available surgical tools, such as a flexible microcatheter for canal dilation and placement of a trabecular tensioning suture may be used during the surgical revision,” he said.

Dr von Wolff said that advances in surgical tools and techniques have dramatically altered the face of glaucoma treatment in recent years.

“In our clinic we have two main groups of glaucoma patients: the patients of the 20th century and those of the 21st century. The 20th century glaucoma patient is one with a diagnosis based on IOP measurements and visual field examinations with a target pressure of 21 mmHg or below whose medical options were limited. If surgery was performed for these patients, it was usually performed at an advanced stage in the disease. And the main problem with this group of patients is that we had progression of the disease,” he said.

By contrast, Dr von Wolff said that for the 21st century glaucoma patient the aim has shifted to prevention of the disease by early diagnosis, close monitoring of the progression of the disease, aggressive IOP

lowering and early surgery if the disease progresses or if the target pressure is not reached.

In order to justify early surgery in glaucoma, Dr von Wolff emphasised that the surgery needs to fulfil certain criteria.

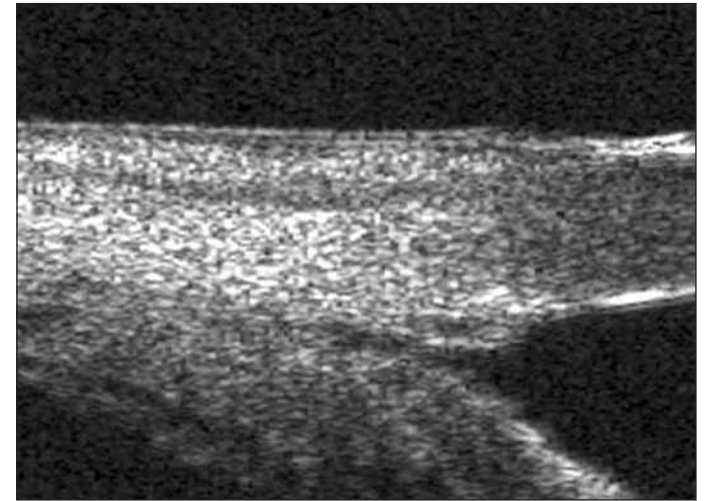
“It should be effective in lowering IOP, it should be safe with minimal side effects, it should be long lasting, and if possible, a revision should be able to be performed at a later stage,” he said.

One of the main advantages of viscocanalostomy, added Dr von Wolff, is the fact that the watertight closure results in no bleb and none of the side effects of filtration, including tissue atrophy and scarring.

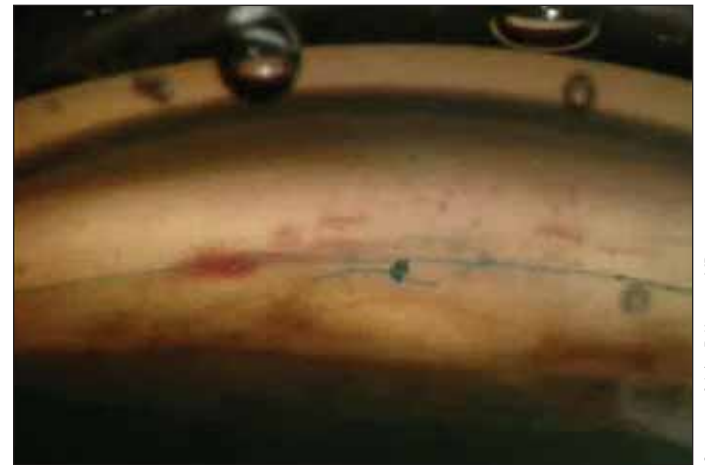“It [surgery] should be effective in lowering IOP, it should be safe with minimal side effects, it should be long lasting, and if possible, a revision should be able to be performed at a later stage”

Kurt-Dietrich von Wolff MD, FRCO

Using video footage, Dr von Wolff showed how dissection of the original scleral flap exposes the previous surgical access to Schlemm's canal and the trabecular meshwork, allowing evaluation and surgical repair of the aqueous humour flow path.



High definition ultrasound image of the angle area showing the invagination of the trabecular meshwork by the circumferential cinching suture placed in Schlemm's Canal by the viscodilating microcatheter and tied with tension on the suture



Post-op gonioscopic view of the angle including the trabecular meshwork and the intracanalicular cinching tension suture in Schlemm's Canal

He said that the technique was easily and rapidly performed in multiple eyes, even several years after the original surgery.

“The reopened surgical site allows the use of a flexible microcatheter to be advanced into Schlemm's canal to dilate 360 degrees of the canal and place a suture to tension the trabecular meshwork and maintain the canal lumen. The surgical revision was visibly effective in restoring aqueous flow and reducing IOP post-surgically,” he concluded.

manfred.tetz@charite.de
info@augenklinik-grosspankow.de
ccc@superior.net