



I. Howard Fine

Cheryl Guttman
in Paris

BIMANUAL microincision phacoemulsification instrumentation and techniques are proving valuable in the management of a variety of challenging situations, according to I. Howard Fine MD.

Dr. Fine will demonstrate how a bimanual microincision approach enabled completion of cases complicated by zonular weakness or dialysis and recurrent microhyphaema in a presentation at the XXII Congress of the ESCRS

He will also discuss using bimanual microincision phaco as a tool for optimising the safety of lens removal in eyes undergoing refractive lens exchange.

"Bimanual microincision surgery offers improved fluidics along with enhanced chamber stability, and it greatly minimises incisional outflow so that it approaches the ideal scenario of operating in a completely closed system. Because of those reasons, surgeons can use it to their advantage in a variety of difficult scenarios," said Dr. Fine, clinical associate professor of ophthalmology, Casey Eye Institute, Oregon Health Sciences University, Eugene.

In any eye where there is zonular damage, capsulorhexis creation can be performed more easily, safely, and accurately using the microincision capsulorhexis forceps designed for placement through a 1.2-mm incision.

Since no viscoelastic leaves the eye, there are no fluctuations in the anterior chamber.

Consequently, the capsular opening can be made very precisely without trampolineing the lens and causing stress on the remaining zonular fibres.

"There is a learning curve for this technique because the surgeon has to use the fingers instead of the wrist. However, the fact is the fingers are much more skilled, and I have been amazed at how precise and round the capsulorhexis is when made using this approach," Dr. Fine said.

Two microincision capsulorhexis forceps are available on the market – the Fine-Hoffman forceps (Microsurgical Technology)

Bimanual microincisional surgery affords benefits in diverse situations

and the Fine-Ikeda forceps (ASICO).

Cataract removal has also been facilitated in eyes with zonular dialysis using bimanual microincision techniques and technology, Dr. Fine said.

He illustrated that point with two cases, the first featuring a subluxated, posteriorly prolapsed lens associated with torn zonules in all but the inferior quadrant. In that eye, Dr. Fine first used viscoelastic to elevate the lens and capsule into the anterior chamber by placing the Viscoat cannula through one microincision and an irrigating handpiece through the other. He then slightly constricted the pupil and performed bimanual phacoemulsification to remove the cataract.

Next, he performed vitrectomy using a microincision high-speed vitrector, and introduced a foldable IOL through a 2.5 mm incision created between the two bimanual microincisions. To implant the lens, he placed the haptics through the pupil and sutured them to the iris while leaving the optic in the anterior chamber. He then gently nudged the optic behind the pupil.

In another case of a patient who had suffered traumatic zonular dialysis superiorly, the versatility and control afforded by bimanual microincision phaco enabled Dr. Fine to pull the anterior chamber contents toward, versus away from, the area of dialysis in order to minimise stress on the residual zonular fibres. In that case, the zonular dialysis was located to the left and would become stressed when working temporarily with his right hand holding the phaco tip and the aspirator held in his left. To resolve that situation, Dr. Fine simply switched instruments between his two hands.

"As in all cases of zonular weakness, I began by performing a capsulorhexis using a microincision technique, and then in this case I placed a capsular tension ring and hydro-expressed the lens out of the bag. However, as I began phaco and as soon as the

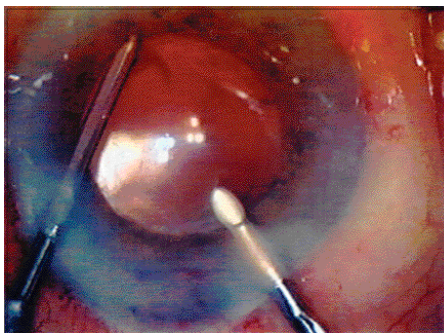
aspiration came on, all of the intraocular contents would be pulled toward the phaco tip in my right hand. Faced with the potential for unzipping the attached zonules that were located toward the left, I instead used the phaco tip in my left hand and aspirator in my right so the intraocular contents would move in the direction of the zonular dialysis and allow them to remain relaxed," he explained

he could identify its sites of origin and use wet field cautery to achieve haemostasis.

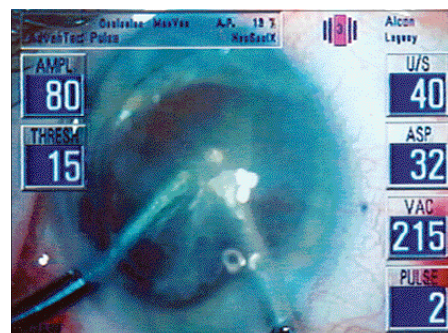
Dr. Fine also cited the efficiency and safety of bimanual microincision surgery for refractive lens exchange in eyes with a very soft nucleus. In that situation, his technique involves creation of two microincisions that are almost at a right angle to each other – the left microincision is made almost horizontally and the microincision

throughout the entire procedure further enhances safety since it minimises the risk of trampolineing the vitreous face and causing cystoid macular oedema.

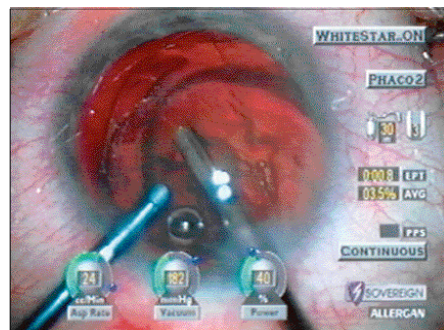
"While it may seem counterintuitive, it is actually more difficult to perform coaxial phacoemulsification on a soft nucleus compared with a 2 or 3+ nuclear sclerotic cataract because the soft nucleus cannot be chopped and does not behave predictably.



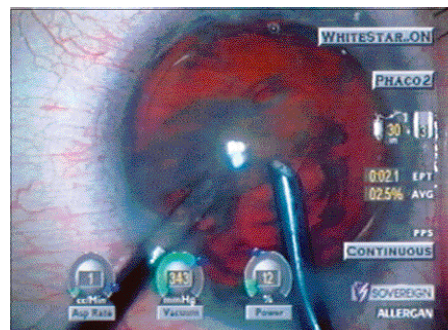
Cautery of a bleeding point at the margin of the iris after identifying it by pinching the infusion tubing on the irrigator.



Bimanual micro-incision phacoemulsification of a lens prolapsed into the anterior chamber from its subluxed position within the vitreous cavity.



Movement of all of the anterior chamber toward the phaco tip when aspiration and vacuum are on widening the dialysis to the left.



Use of the phaco tip in the left hand which closes the dialysis during phacoemulsification of the cataract.

In a case where bleeding developed around the iris periphery following pupillary stretching, Dr. Fine used bimanual microincision instrumentation to effectively treat the microhyphaema intraoperatively.

After making two side port incisions, he placed the irrigator through one and a microcautery device through the other and let the infusion from the irrigator flow in until the IOP rose high enough to stop the bleeding. Next, he pinched the infusion tubing, allowing the eye to soften and causing the bleeding to restart so

on the right is made to be almost vertical.

After creating the capsulorhexis and performing cortical cleaving hydrodissection to bring the nucleus out of the bag into the plane of the capsulorhexis, he places the phaco needle on the equator of the nucleus to the right and uses it in concert with the irrigator to carousel the lens.

With that approach, lens removal is achieved without phaco power in most cases and at a site that is remote from the posterior capsule and corneal endothelium. In addition, keeping the irrigator in the eye

using a bimanual technique after performing cortical cleaving hydrodissection, it is possible to simply tilt the needle back into the capsule and remove the entire cortical envelope in the plane of the capsulorhexis in a single gulp using fluidics alone," Dr. Fine said.

hfine@finemd.com