




Supplement
February 2022



Education
FORUM



NEW MEDICAL THERAPIES
and Modern MIGS Address Unmet Needs in

GLAUCOMA

and **CATARACT**

PATIENT CARE

ASSESSING BASELINE TRENDS IN THE TREATMENT OF PATIENTS WITH GLAUCOMA AND CATARACTS

Survey reports trends in clinical practice. | Boris Malyugin, MD

According to the 2020 ESCRS Clinical Trends Survey, an average of 21% of patients prescribed one or two topical glaucoma medications and 27% of those prescribed more than two topical glaucoma medications to control their condition are not compliant (Figure 1). It is a significant number of patients.

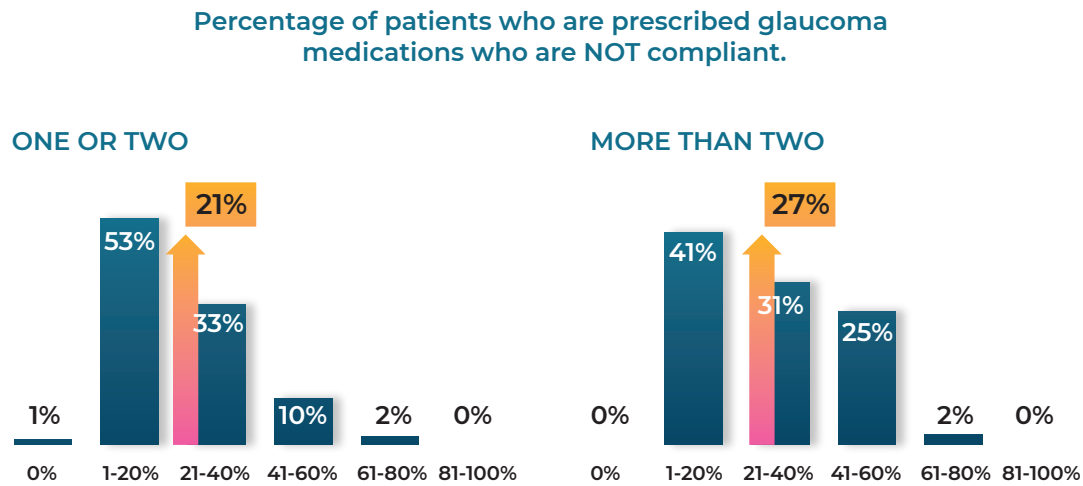


Figure 1. Respondents to the 2020 ESCRS Clinical Trends Survey believe that on average 21% of patients who are prescribed ONE OR TWO topical glaucoma medications and 27% of patients who are prescribed MORE THAN TWO topical glaucoma medications are NOT compliant.

The survey was performed in autumn of 2020 online, containing 145 questions, with 392 delegates responding. On average respondents saw 28 patients with glaucoma per month, and they estimated that 11% of their patients with cataracts also have glaucoma.

Respondents further estimated that 11% of their patients having cataract surgery who are using topical glaucoma medications would be candidates for a

minimally invasive glaucoma surgery (MIGS) device.

In 2020 53% of delegates used MIGS in their patients having cataract surgery or planned to incorporate the procedure within the next 12 months.

In this evidence-based supplement, top experts will review how new medical therapies and modern MIGS will help ophthalmologists address unmet needs in patients with glaucoma and cataracts.

“Respondents further estimated that 11% of their patients having cataract surgery who are using topical glaucoma medications would be candidates for MIGS.”

— Boris Malyugin, MD



Boris Malyugin, MD, is professor of ophthalmology, deputy director general (R&D6 Edu), S. Fyodorov Microsurgery Complex, Moscow, Russia. His financial disclosures include Alcon, Santen, Senju, MST, Morcher, Ziemer, and Zeiss. He can be contacted at boris.malyugin@gmail.com.

BEST PRACTICES FOR GLAUCOMA SCREENING AND MONITORING: THE IMPORTANCE OF EARLY DIAGNOSIS

A complete examination helps detect glaucoma early. | Roberto Bellucci, MD

Glaucoma is not easily detected, hence it's critical to diagnose glaucoma and reduce intraocular pressure (IOP) early to prevent vision loss and continued progression.

DIAGNOSTIC AND MONITORING TOOLS

A complete eye examination is necessary for diagnosis and establishing a baseline, as well as round-the-clock IOP testing.

Basic diagnostics include applanation tonometry or pneumotonometry. Gonioscopy is needed to visualize the anterior chamber angle in true color, and dynamic gonioscopy may reveal angle closure risk.

Corneal thickness may be measured with ultrasound pachymetry (gold standard), anterior segment OCT, or other methods. Thinner corneas are associated with greater risk for glaucoma.

We use ophthalmoscopy to examine the optic nerve head (ONH) and especially optical coherence tomography (OCT) to measure the retinal nerve fiber layer (RNFL) thickness. RNFL monitoring is useful in mild to

“Functional changes are apparent with visual field imaging in moderate to advanced cases, while the monitoring of late-stage glaucoma remains a challenge.” — Roberto Bellucci, MD

moderate glaucoma, while the OCT study of macular thickness and of the ganglion cell layer is employed for advanced cases.

Visual field testing has dominated the screening and monitoring of glaucoma at the subjective level. Various analyses are available for the visual field evaluation, including the glaucoma hemifield test (GHT) for early cases, and the pointwise regression (PLR and PER) for more advanced cases. If we find discrepancies between the objective and the subjective tests, we can use magnetic resonance imaging of the optic pathway to check the retro-ocular visual system.

Additional testing may include anterior segment OCT/Scheimpflug, ultrasound biomicroscopy to visualize ciliary processes or diagnose postoperative malignant glaucoma, and visual evoked response to help stage glaucoma. These tests may shed light on particular cases like angle-closure glaucoma or ciliary block glaucoma.

TRACKING PROGRESSION

We can detect structural changes of the ONH, RNFL, and macula using OCT in mild to moderate glaucoma (Figure 2). OCT angiography also may help track progression, and OCT of the macula can help monitor advanced glaucoma. Functional changes are apparent with visual field imaging in moderate to advanced cases, while the monitoring of late-stage glaucoma remains a challenge.

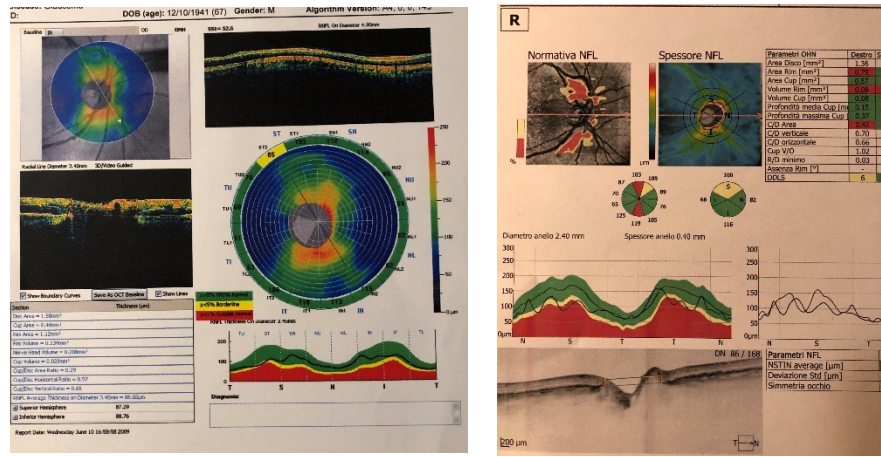


Figure 2. OCTs (left, 2009; right, 2021) from a patient with pseudoexfoliation glaucoma. Source: Roberto Bellucci, MD.



Dr. Bellucci is professor of ophthalmic surgery, Verona, Italy. He has no financial disclosures related to this article. He can be contacted at roberto.bellucci52@gmail.com.

CURRENT AND EMERGING PHARMACOLOGICAL THERAPY OPTIONS: ADDRESSING UNMET NEEDS

Combination drugs may address compliance issues. | Simonetta Morselli, MD

Poor patient compliance is a major obstacle in glaucoma therapy, impeding the effectiveness of treatments in slowing progression and potential vision loss. A monotherapy study found that 25% of patients took less than 75% of their doses; almost 20% of patients took less than 50% of their doses.¹

Patients may struggle to instill multiple medications or have conditions inhibiting instillation. Medications also can cause detrimental long-term conjunctival effects.

ASSESSING OPTIONS

According to the Collaborative Initial Glaucoma Treatment Study, more than 75% of patients need two or more medications after 2 years.² The Ocular

Hypertension Treatment Study reported after 5 years, 49% of patients need two or more medications to reduce intraocular pressure (IOP) by 20%.³

Fixed combinations can increase compliance. Prostaglandin-timolol has been effective, and new drug classes are emerging. Nitric oxide donating prostaglandin divides into latanoprost, acting on the uveoscleral pathway, and nitric oxide, relaxing the trabecular meshwork and scleral channel. Netasudil, a ROCK inhibitor, relaxes the trabecular meshwork and increases trabecular outflow.

Figure 3 shows the most common adverse reactions to latanoprostene bunod 0.024% and timolol maleate 0.5% in the APOLLO and LUNAR studies. IOP pressure reduction was very high with latanoprostene bunod compared with timolol alone.

Most Common Ocular Adverse Reactions in the APOLLO and LUNAR Studies

Adverse Reactions (%)	APOLLO		LUNAR	
	LBN	TIMOLOL 0.5%	LBN	TIMOLOL 0.5%
Eye Irritation	3.9	2.2	7.2	4.4
Conjunctival Hyperemia	2.8	1.5	9.0	0.7
Eye Pain	1.4	2.2	5.8	3.7
Instillation Site Pain	1.1	1.5	1.4	—

Figure 3. APOLLO and LUNAR safety data. Weinreb RN, et al. Ophthalmology. 2016; 123(5):965-973; Medeiros FA, et al. Am J Ophthalmol. 2016;168:250-259. Source: Simonetta Morselli, MD.

When a fixed combination of netarsudil and latanoprost was used, three times as many patients had a reduction in IOP of 40% or more compared with latanoprost alone.⁴ The IOP-reduction effects of the combination were better than each individual active component. In a pooled analysis of MERCURY-1 and MERCURY-2, ocular adverse events reported in 5% or more patients generally were higher with the fixed combination compared with only one drug.⁵ Latanoprost without BAK can reduce ocular side effects, and the mean baseline IOP was the same as with latanoprost with preservative.^{6,7}

CONCLUSION

Poor patient compliance must be addressed in glaucoma care. New drug classes may improve efficacy, and preservative-free formulations have the potential to decrease the side effects of topical drops.



Dr. Morselli is chief of ophthalmology, San Bassiano Hospital, Bassano del Grappa, Italy. She is a consultant for Alcon and Bausch & Lomb. She can be contacted at simonetta.morselli@gmail.com.

REFERENCES

1. Okeke CO, et al. Adherence with topical glaucoma medication monitored electronically the Travatan Dosing Aid study. *Ophthalmology*. 2009;116(2):191-199.
2. Lichter PR, et al. Interim clinical outcomes in the Collaborative Initial Glaucoma Treatment Study comparing initial treatment randomized to medications or surgery. *Ophthalmology*. 2001;108:1943-1953.
3. Kass MA, et al. The Ocular Hypertension Treatment Study: a randomized trial determines that topical medication delays or prevents the onset of primary open-angle glaucoma. *Arch Ophthalmol*. 2002;120:701-713.
4. Rocklatan (netarsudil and latanoprost ophthalmic solution) 0.02%/0.005% Prescribing Information, Aerie Pharmaceuticals, Inc., Irvine, Calif, 2019.
5. Bacharach J, et al. Presented at the 13th Biennial Meeting of the European Glaucoma Society; May 19–22, 2018; Florence, Italy.
6. XELPROS [package insert]. Cranbury, NJ: Sun Pharmaceutical Industries, Inc.; 2018.
7. Data on file. Cranbury, NJ: Sun Pharmaceutical Industries, Inc.

SUSTAINED-RELEASE DEVICES AND KEYS TO INCORPORATING THEM INTO YOUR PRACTICE

Technologies may help overcome limitations of topical drugs. | Andrew Tatham, MD

Topical glaucoma treatments have many limitations that may impact efficacy.

The average drop has a volume of 50 µl, so 20 µl is lost immediately because the ocular surface can only accommodate 30 µl. In addition, the medication must navigate through the cornea and much of it is lost through the nasal lacrimal drainage system. Therefore, only approximately 5% of the drug reaches the target tissue.

In addition, some patients may not be able to instill drops or do not administer them properly, touching the eye with the bottle or missing the eye completely. Patients also can be poorly adherent in administering drops or may not tolerate them well.

Compared with topical glaucoma medications, sustained-release devices may help improve adherence and tolerability, provide sustained control of intraocular pressure (IOP), and increase target tissue concentrations.

SUSTAINED-RELEASE DEVICES

Several sustained-release options are in development.

The topical ophthalmic drug delivery device (TODDD) is placed under the upper eyelid, slowly releasing medication. Though non-invasive, a potential limitation is that were it to become dislodged, the patient and clinician may be unaware that medication was no longer being delivered.

The iDose TR is a titanium implant surgically anchored to the sclera under gonioscopic view. It releases travoprost for 12 months and, when empty, can be removed and replaced.

The fully biodegradable OTX-TIC travoprost intracameral implant is injected into the anterior chamber with a 26- or 27-gauge needle, remaining in the iridocorneal angle. It dissolves over time, not requiring removal.

The bimatoprost sustained-release intracameral implant is the only FDA-approved sustained-release glaucoma medication. It uses biodegradable polymers similar to dissolvable sutures. The device is inserted into the anterior chamber, where it slowly dissolves to water and carbon dioxide.

“Sustained-release formulations could help overcome limitations associated with topical glaucoma medications and deliver high concentrations of medication to target tissues.” — Andrew Tatham, MD

CONCLUSION

Sustained-release formulations could help overcome limitations associated with topical glaucoma medications and deliver high concentrations of medication to target tissues. However, there are potential challenges (Figure 4). Sustained-release devices could be particularly useful for patients poorly adherent or intolerant of topical medications. They can enable enhanced ocular penetration and provide sustained therapeutic levels of medication, while potentially minimizing ocular surface adverse effects. Questions remain about optimal dosing frequency, optimal patient selection, and whether they will be cost effective.

Challenges of Sustained-Release Medications

- Risks associated with intraocular procedure
- Optimal dosing frequency still to be determined
- Yet to determine which patients will benefit most
- Unclear if they will be cost effective

Figure 4. Challenges of sustained-release medications. Source: Andrew Tatham, MD

Dr. Tatham practices at Princess Alexandra Eye Pavilion, Edinburgh, Scotland, and the University of Edinburgh, Edinburgh, Scotland. He is a speaker for Santen, Thea, Allergan, Glaukos, Sight Sciences, Heidelberg Engineering, and Ivantis; he is a consultant for Allergan, Santen, Thea, and Glaukos; and he receives grant/research support from Allergan. He can be contacted at andrewjtatham@gmail.com.



LATEST MIGS TECHNOLOGIES: COMBINING SURGERY IN PATIENTS WITH GLAUCOMA AND CATARACTS

Devices safely help overcome treatment compliance obstacles. | Iqbal Ike K. Ahmed, MD, FRCSC

During the last decade, we have moved toward interventional glaucoma management, treating patients earlier with safer options that address adherence and achieving lower intraocular pressures (IOPs).

Minimally invasive glaucoma surgery (MIGS) has been associated with a high safety profile and rapid recovery. It is minimally traumatic and typically implanted ab-interno. It can be used early because of its high degree of safety.

We also have microinvasive bleb surgery (MIBS), which is typically used for moderate to advanced cases before trabeculectomy.

MIGS and MIBS fit the middle ground between minimal and significant IOP lowering.

MIGS devices are differentiated by outflow target. Classical MIGS target Schlemm's canal (Figure 5) and the supraciliary space. As you move to the subconjunctival space, we think of MIBS.

“MIGS may be useful in older patients with mild to moderate glaucoma with compliance or tolerability issues.” — Iqbal Ike K. Ahmed, MD, FRCSC

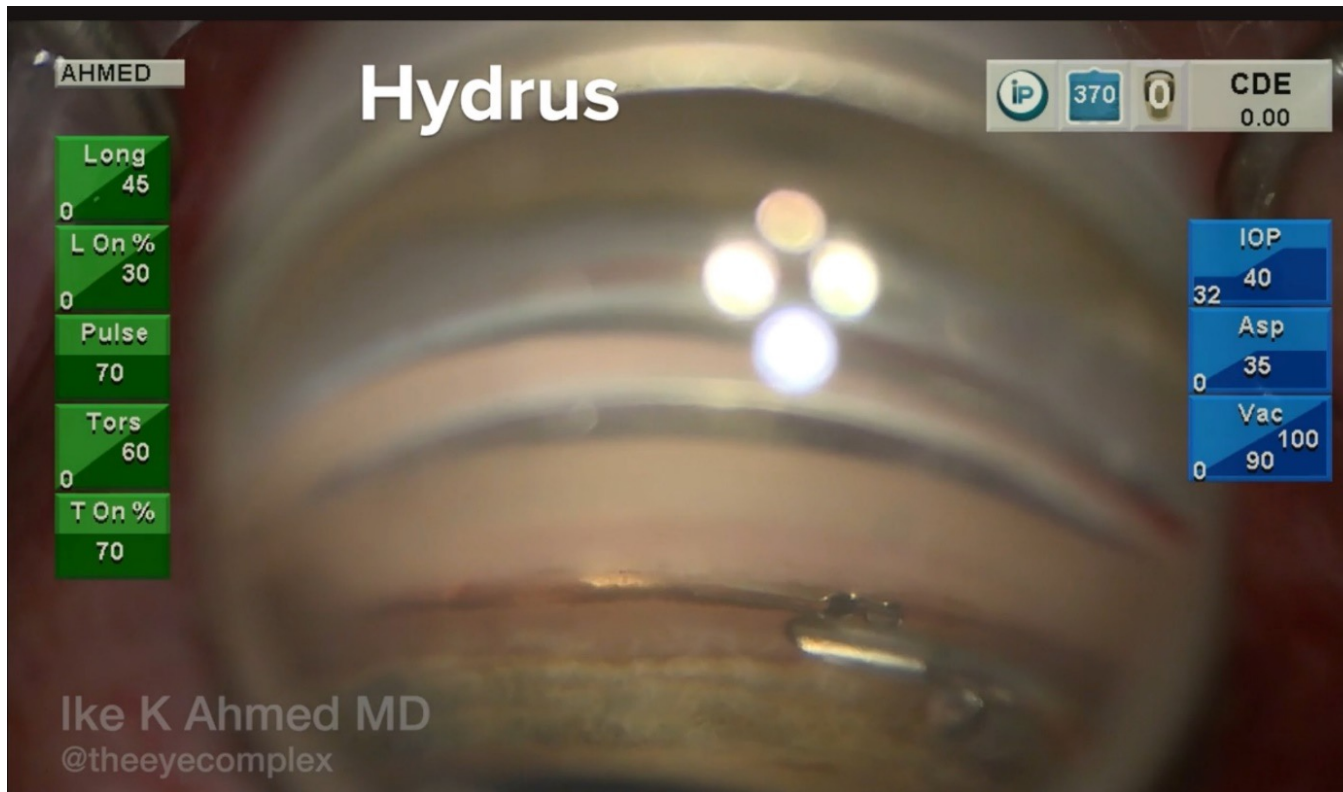


Figure 5. The Hydrus device dilates and scaffolds Schlemm's canal and provides windows to allow the trabecular meshwork to have unimpeded flow. Source: Iqbal Ike K. Ahmed, MD, FRCSC.

We typically combine MIGS with cataract surgery, which has a good synergy. MIGS may be useful in older patients with mild to moderate glaucoma with compliance or tolerability issues. MIGS enables future surgery, if necessary.

Patient selection and treatment goals are important considerations. Key factors include positioning and optimizing access and visualization. We need to prevent postoperative hyphema and consider how variabilities associated with distal outflow resistance and healing may limit the efficacy of these procedures.

CONCLUSION

Trabeculectomy is the gold standard. MIGS procedures are less potent but provide a non-bleb and safer option that can work synergistically with cataract surgery. MIBS procedures balance risk and benefit and are more potent than MIGS but reduce IOP with a bleb in a more controlled way, with better bleb morphology and postoperative intensity.

The most critical concept is that we are shifting our approaches to early intervention for patients having cataract and standalone procedures.



Dr. Ahmed is assistant professor and director of the Glaucoma and Anterior Segment Surgery Fellowship, University of Toronto; division head, Ophthalmology, Trillium Health Partners; and medical director, Prism Eye Institute. His financial disclosures include Aequus, Aerie, Alcon, Allergan, ArcScan, Bausch Health, Beaver Visitec, Beyeonics, Carl Zeiss, Centervue, CorNeat Vision, Ellex, ELT-Sight, ElutiMed, Equinox, Genentech, Glaukos, Gore, InjectSense, Iridex, iStar, Ivantis, Johnson & Johnson, KeLoTec, LayerBio, Leica Microsystems, MicroOptx, MST Surgical, New World Medical, Ocular Instruments, Omega Ophthalmics, PolyActiva, Sanoculis, Santen, Science Based Health, Sight Sciences, Stroma, ViaLase, and Vizzario. He can be contacted at ikeahmed@mac.com.

Independent medical education supported by AbbVie and Ivantis.