

IME SUPPLEMENT | FEBRUARY 2023

EUROTIMES



A CORNEAL REFRACTIVE UPDATE

on Lenticule Extraction Technology and Outcomes



Clinical Trends in Corneal Refractive Surgery in Europe

BURKHARD DICK, MD, PHD, FEBOS-CR

The European Society of Cataract and Refractive Surgeons (ESCRS) recently published a 6-year assessment of practice patterns and clinical opinions among ESCRS delegates from 2016 to 2021.¹ The study compiled all the data gathered from the ESCRS Clinical Trends Surveys to identify significant trends across the entire membership. They also performed cross-tabulation analyses to determine whether trends varied by key demographic and practice differentiators.¹ The insights they were able to derive from these data clearly highlighted the value of conducting these surveys.

The analysis revealed that the average volume of corneal refractive procedures decreased slightly from 130 in 2016 to 108 in 2021.^{1,2} Except for 2020, this average volume has been relatively stable since 2018. In 2021, the survey found that 31% of delegates in Eastern Europe most commonly performed wavefront-optimised procedures, whereas 35% of delegates in Western Europe commonly performed standard ablations, followed closely wavefront-optimised procedures (Fig. 1).

Almost 20% of clinicians rarely check the ocular surface or only do so when the patients present with dry eye symptoms.

A healthy ocular surface is key to the success of several ocular interventions, including cataract and refractive surgeries. Indeed, 92% of survey respondents agreed or strongly agreed that mild to moderate dry eye significantly affects patient satisfaction following cataract and refractive surgeries.¹ As such, it is somewhat surprising that only 61% of delegates systematically check the ocular surface during preoperative exams for all patients undergoing laser-based vision correction.

Almost 20% of clinicians rarely check the ocular surface or only do so when the patients present with dry eye symptoms.¹ We know that dry eye symptoms peak immediately after refractive surgery,³ but optimising the ocular surface prior to performing surgery can help ameliorate the degree to which patients are impacted by postoperative dry eye.⁴ A large portion of patients have asymptomatic ocular surface disease (OSD) before surgery but are undiagnosed. This is

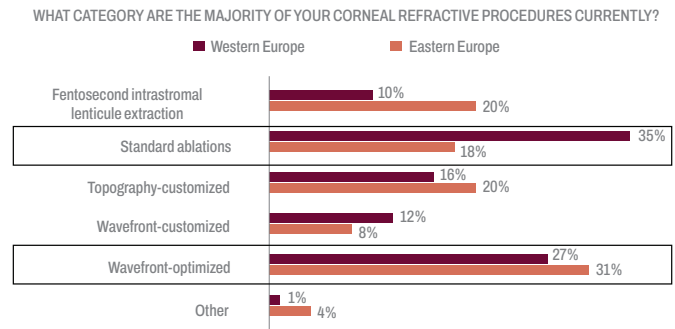


FIGURE 1: IN 2021, THE MAJORITY OF ESCRS DELEGATES IN EASTERN EUROPE PERFORMED WAVEFRONT-OPTIMISED REFRACTIVE PROCEDURES WHEREAS THOSE IN WESTERN EUROPE MOSTLY PERFORMED STANDARD ABLATIONS.¹

strong incentive for clinicians to routinely perform these preoperative checks.^{4,5}

Dr. Burkhard Dick is the Chair of the Department of Ophthalmology at the University of Bochum and Director of the University Eye Clinic. He can be contacted at burkhard.dick@kk-bochum.de

Dr. Dick has served as a consultant for Acufocus, Avellino, Bausch + Lomb, EuroEyes, Excel, Johnson & Johnson, Microptx, Orasis Pharmaceuticals, RxSight, and Carl Zeiss Meditec, receives royalties from Morcher and Oculus; has stock options in Acufocus, Excel, RxSight, Shifamed, and Vivior; intellectual property/rights in Geuder, Johnson & Johnson, Morcher, Oculus, and Carl Zeiss Meditec; receives grant/research support from Acufocus, Bausch + Lomb, Bayer, Domilens, Hoya, Implants, Johnson & Johnson, Microptx, Novartis, Oculus, RxSight, and Carl Zeiss Meditec.

REFERENCES:

1. Kohnen T, et al. ESCRS Clinical Trends Survey 2016-2021: A six-year assessment of practice patterns amongst society delegates. J Cataract Refract Surg. 2022.
2. European Society of Cataract and Refractive Surgeons (ESCRS) Clinical Survey 2021.
3. Shtein RM. Post-LASIK dry eye. Expert Rev Ophthalmol. 2011;6:575-82.
4. Mah F. Managing dry eye postop begins preop. Review of Ophthalmology. Jun 2020. www.reviewofophthalmology.com/article/managing-dry-eye-postop-begins-preop.
5. Starr CE, et al. An algorithm for the preoperative diagnosis and treatment of ocular surface disorders. J Cataract Refract Surg. 2019;45(5):669-84.



The Fundamentals of Lenticule Extraction

PAVEL STODULKA, MD, PHD, FEBOS-CR

Advances in refractive surgery are driven by innovations in femtosecond laser technology. Specifically, refractive corneal lenticule extraction (LE) is a relatively new class of keratorefractive procedures

that is gaining popularity. In LE, femtosecond lasers perform vision correction by extracting a refractive lenticule (disc-shaped piece of corneal tissue) without creating a corneal flap.

What are the laser options in the field?

The first femtosecond laser for a LE procedure was the VisuMax (Carl Zeiss Meditec), which received the Conformité Européenne (CE) mark in 2011 for myopia correction and, as such, is the most advanced and well-studied procedure in the field.¹ The company termed the procedure refractive lenticule extraction (ReLEx) and then small incision lenticule extraction (SMILE).

It was only in 2020 that two additional lasers for LE received the CE mark. The first was the FEMTO LDV Z8 (Ziemer Ophthalmic Systems AG) and the procedure was termed corneal lenticule extraction for advanced refractive correction (CLEAR). The second was ATOS (Schwind eye-tech-solutions) with a procedure called SmartSight.¹ Another laser, ELITA, (Johnson & Johnson Vision) is expected to receive the CE mark soon, with the proposed procedure name of smooth incision lenticule keratomileusis (SILK).

Having different company-proposed terms for the same medical procedure creates confusion among patients and doctors. Since these procedures have the same underlying principle, despite using different femtosecond lasers, I strongly suggest using overarching terms to avoid confusion amongst patients.

How does LE work?

All LE procedures use femtosecond lasers to define the lenticule surfaces and a small incision through which the lenticule can be extracted (Fig. 2). Once extracted, the shape of the corneal surface changes which, in turn, corrects refractive error. For myopia correction, the lenticule is thicker in the centre and thinner in the periphery.²

LE produces less corneal nerve damage which allows faster recovery of corneal nerve sensitivity and decreases the incidence of postoperative dry eye.

Why is LE becoming increasingly popular?

Prior to LE procedures, laser refractive surgery could already achieve excellent visual outcomes and deliver high levels of patient satisfaction. Therefore, refractive surgeons have a high threshold for success. Similar to LASIK, LE surgeries and postoperative recovery are painless, LE procedures are precise, and the time taken for visual rehabilitation is 1-2 days (with some platforms). However, the biggest difference between LE and LASIK is that LE is inherently less invasive and this confers additional benefits. First, there are no flap-related complications. Second, LE results in potentially better preservation of corneal biomechanical integrity and stability. Third, LE produces less corneal nerve damage which allows faster recovery of corneal nerve sensitivity and decreases the incidence of postoperative dry eye.³⁻⁷ This is a key advantage of LE over LASIK because postoperative dry eye significantly affects treatment outcomes and patient satisfaction. Fourth, LE offers better spherical aberration control.⁵⁻⁷ Fifth, LE creates a larger functional optical zone (FOZ), which is potentially more forgiving of decentration

issues and could reduce pupil-related photopsia. Lastly, LE only requires a femtosecond laser, as opposed to the femtosecond and excimer lasers for LASIK.

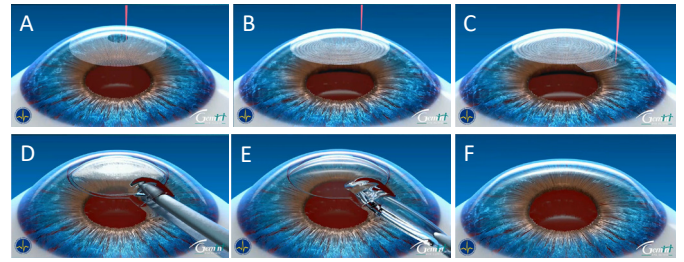


FIGURE 2: GENERALISED PROCEDURE FOR LENTICULE EXTRACTION. A FEMTOSECOND LASER IS USED TO DELINEATE (A) THE POSTERIOR AND, (B) ANTERIOR SURFACE OF THE LENTICULE AND (C) A SMALL INCISION THROUGH WHICH (D AND E) THE REFRACTIVE LENTICULE CAN BE EXTRACTED. (F) THE CORNEAL SURFACE IS ALTERED TO ACHIEVE THE DESIRED VISION CORRECTION. COURTESY OF PAVEL STODULKA, MD, PHD, FEBOS-CR.

Aiming for success

While greater experience with LE will undoubtedly increase a surgeon's ability to manage complications and generate consistently successful outcomes, a few other considerations can also improve the chances of success. Laser settings are paramount, though they will vary between the different femtosecond lasers and must be fine-tuned specifically to each laser. In general, lower laser energy levels with proper spot/track spacing is desirable. Optimising these parameters was a major advancement with early LE procedures as it significantly improved postoperative visual recovery without impacting the ease of the procedure.^{9,10} We have also found that limiting the number of preoperative eyedrops is useful because excessive eyedrop usage can affect epithelial transparency and the resultant stromal edema can lead to under-correction.

What's in store for LE?

Recent innovations in the LE field have included faster lasers that result in shorter procedures (e.g., 10 seconds), cyclotorsion compensation, automatic centration, and separate entry for the upper and lower interfaces, which can be appealing to surgeons who are newer to the technique.

Given that LE generates a precise stromal lenticule, which is typically discarded, and the increasing popularity of the procedure over the years, some studies have looked to repurpose this human donor tissue in 'tissue-added' surgeries, such as keratoconus or even refractive surgery. Biological inlays have the advantage of biocompatibility, retaining nutrient flow, and lower risk of immune rejection;¹¹ however, the refractive outcomes following stromal remodelling remain unpredictable.¹²⁻¹⁴ On the other hand, since precise refractive targets are not required for patients with advanced keratoconus, the refractive stability provided by the lenticule may stave off the need for corneal transplantation.^{15,16}

Upcoming indications for LE could include the treatment of hyperopia and presbyopia. Clinical evidence to support the use of LE to correct hyperopia has been submitted and is currently awaiting the CE mark, whereas a clinical study to explore presbyopic LE is currently being planned. The next major frontier in

this field may include robotic assistance. A robotic femtomatrix laser could perform LE in 5 seconds. This technology is likely to disrupt both cataract and refractive surgery.

In summary, LE is a technique that has been practiced for over a decade but mostly with a single platform. The recent availability of newer platforms, with more on the way, could improve overall access to the technique for clinicians and patients. However, it will also require us to become more familiar with each platform so that we can gauge how they might perform in our hands and for our patients.

Dr. Pavel Stodulka is the Founder, Chief Surgeon, and CEO of the Gemini Eye Clinics in the Czech Republic and Austria. He can be contacted at stodulka@lasik.cz

Dr. Stodulka has served as an investigator for a clinical study of hyperopic lenticule extraction and currently serves as an investigator for the clinical study of presbyopic lenticule extraction for Carl Zeiss Meditec.

REFERENCES:

1. Fuest M, Mehta JS. Advances in refractive corneal lenticule extraction. *Taiwan J Ophthalmol.* 2021;11(2):113-21.
2. Reinstein DZ, et al. *The surgeon's guide to small incision lenticule extraction (SMILE)*. Thorofare, New Jersey: SLACK Incorporated; 2018.
3. Wong AH, et al. Dry eyes after SMILE. *Asia Pac J Ophthalmol.* 2019;8(5):397-405.
4. Liu YC, et al. Comparison of tear proteomic and neuromediator profiles changes between small incision lenticule extraction (SMILE) and femtosecond laser-assisted in-situ keratomileusis (LASIK). *J Adv Res.* 2021;29:67-81.
5. Vestergaard AH, et al. Efficacy, safety, predictability, contrast sensitivity, and aberrations after femtosecond laser lenticule extraction. *J Cataract Refract Surg.* 2014;40:403-11.
6. Sekundo W, et al. One-year refractive results, contrast sensitivity, high-order aberrations and complications after myopic small-incision lenticule extraction (ReLEx SMILE). *Graefes Arch Clin Exp Ophthalmol.* 2014;252:837-43.
7. Moshirfar M, et al. Small-incision lenticule extraction. *J Cataract Refract Surg.* 2015;41:652-65.
8. Damgaard IB, et al. Functional optical zone and centration following SMILE and LASIK: a prospective, randomized, contralateral eye study. *J Refract Surg.* 2019;35(4):230-7.
9. Ji YW, et al. Lower laser energy levels lead to better visual recovery after small-incision lenticule extraction: Prospective randomized clinical trial. *Am J Ophthalmol.* 2017;179:159-70.
10. Li L, et al. Energy setting and visual outcomes in smile: A retrospective cohort study. *J Refract Surg.* 2018;34:11-6.
11. Ang M, et al. Refractive surgery beyond 2020. *Eye.* 2021;35:362-82.
12. Pradhan KR, et al. Femtosecond laser-assisted keyhole endokeratophakia: correction of hyperopia by implantation of an allogeneic lenticule obtained by SMILE from a myopic donor. *J Refract Surg.* 2013;29(11):777-82.
13. Liu R, et al. Femtosecond laser-assisted corneal small incision allogenic intrastromal lenticule implantation in monkeys: a pilot study. *Invest Ophthalmol Vis Sci.* 2015;56(6):3715-20.
14. Damgaard IB, et al. Biological lenticule implantation for correction of hyperopia: an ex vivo study in human corneas. *J Refract Surg.* 2018 Apr 1;34(4):245-52.
15. Del Barrio JL, et al. Corneal stroma enhancement with decellularized stromal lamellas with or without stem cell recellularization for advanced keratoconus. *Am J Ophthalmol.* 2018;186:47-58.
16. Mastropasqua L, et al. Femtosecond laser-assisted stromal lenticule addition keratoplasty for the treatment of advanced keratoconus: a preliminary study. *J Refract Surg.* 2018;34(1):36-44.



Evaluation of Visual Outcomes After Smooth Incision Lenticule Keratomileusis (SILK)

ROHIT SHETTY, DNB, FRCS, PHD

Smooth incision lenticule keratomileusis (SILK) uses the next-generation ELITA femtosecond laser (Johnson & Johnson Vision) and is designed for tissue-bridge-free incision. It is currently being evaluated for the treatment of myopia and myopic astigmatism, and is still an investigational device as of February 2023. The greatest differentiator between SILK and other LE procedures is the novel ablation profile, i.e., a biconvex shape.

What is SILK?

Unlike the iFS advanced femtosecond laser (Johnson & Johnson Vision) which has a pulse duration of 600-800 femtoseconds and energy of 150 nJ,¹ the ELITA femtosecond laser has a pulse duration approximating 150 femtoseconds and energy of 60 nJ with a spot-to-spot distance of 1 μ m. Uniquely, there is no spot separation, which is achieved through a combination of shorter pulse duration, tighter spot pacing, and smaller spot size, compared to the iFS. This not only results in faster, but also smoother cuts.

As with all LE procedures, the anterior and posterior planes of the lenticule are dissected sequentially; however, the extracted lenticule is biconvex. This novel lenticule

shape was chosen because, theoretically, a biconvex lens has the smallest antero-posterior dimension whereas a meniscus lens has the largest antero-posterior dimension. Mathematical modelling of customized corneal ablations has previously shown that a greater depth of central photobleaching could induce an increase in corneal prolateness, i.e., minimal changes in corneal asphericity (Q-value).² Most human corneas have a prolate elliptical shape whereby they flatten from the centre to the periphery and thus have negative asphericity.² Loss of asphericity has been suggested to be the predominant factor that results in a decrease in functional vision.³ Therefore, the smaller antero-posterior dimensions of a biconvex lenticule may better preserve corneal asphericity and, potentially, lead to better visual outcomes.

Visual acuity and quality outcomes from a two-centre clinical study

Two cohorts of patients with myopia/myopic astigmatism underwent SILK to correct myopia and astigmatism in a prospective, single-arm, non-comparative clinical study. A nomogram was only implemented in cohort two. Based on

interim data from cohort two, surgeons rated the ease of lenticule removal as requiring no or minimal additional dissection in 97% of cases. All cornea were clear at the postoperative day 1 and week 1 visits.

By postoperative month 1, 89% of eyes in cohort two had an uncorrected visual acuity (UCVA) of 20/20 or better. In fact, within 1 week after surgery, 85% and 98% of eyes in cohort two achieved a UCVA of 20/20 or better and 20/25 or better, respectively. All eyes in cohort one were targeted for emmetropia and by postoperative month 3, 90% of eyes had a manifest refractive spherical equivalent (MRSE) within ± 0.5 D of the intended target, with low variability (standard deviation of 0.14 D; Fig. 3A). In cohort 2, after implementation of the nomogram, 90% of eyes had a MRSE within ± 0.5 D of the intended target by postoperative month 1 (standard deviation of 0.28 D; Fig. 3B).

Epithelium remodelling is one of the major changes following refractive surgery.

Quality of vision can be affected by collateral changes in the corneal epithelium and nerves, tear film, and depth of focus. Epithelium remodelling is one of the major changes following refractive surgery. An analysis of eyes from both cohorts showed that there were no epithelial irregularities or hyperplasia after SILK, with preoperative and postoperative only varying by a few microns. In this study, patients demonstrated faster and more optimal regeneration of corneal nerves after SILK than what is typically observed post-LASIK. This may have an added advantage in patients with early dry eye disease, as their corneal nerve fibre length is typically lower. A double-pass aberrometer, which provides an objective clinical evaluation of the eye's optical quality (ocular scatter index [OSI]), showed that

postoperative visual acuity was as good or better than the preoperative status.

We have previously measured the depth of focus of emmetropic, post-LASIK, and post-SMILE eyes at distance (20 feet), intermediate (60 cm), and near (40 cm) targets.⁴ In this study, all measured outcome parameters were comparable between post-SILK and emmetropic eyes within the same age group, i.e., at distance, intermediate, and near targets for spherical power; cylindrical power; spherical equivalent; visual acuity; spherical aberration; defocus aberration, higher-order root mean square (HORMS); and lower-order root mean square (LORMS).

In summary, SILK delivered seamless lenticule removal with either no or minor tissue adhesions. Corneal biomicroscopy was unremarkable on postoperative day 1 and week 1. When a nomogram was implemented, patients undergoing SILK experienced faster visual recovery. SILK also resulted in faster corneal nerve regeneration, good tear film optics, controlled change in asphericity and resulting aberrations, and a postoperative depth of focus similar to emmetropic eyes.

Dr. Rohit Shetty is the Vice Chairman of Narayana Nethralaya, India and Faculty at the Department of Ophthalmology at Maastricht University, the Netherlands. He can be contacted at drrohitshetty@yahoo.com

Dr. Shetty has financial disclosures pertaining to Carl Zeiss Meditec, Alcon, Allergan, Novartis, Johnson & Johnson, Alcon Indian Council of Medical Research, and the Department of Biotechnology (Government of India).

REFERENCES:

1. Johnson & Johnson Vision. iFS Advanced Femtosecond Laser. 2019. www.jnjvisionpro.com/sites/us/files/public/Products/updated_ifs_laser_specification_sheet_final.pdf
2. Gatinel D, et al. Analysis of customized corneal ablations: theoretical limitations of increasing negative asphericity. Invest Ophthalmol Vis Sci. 2002;43(4):941-8.
3. Holladay JT, et al. Functional vision and corneal changes after laser in situ

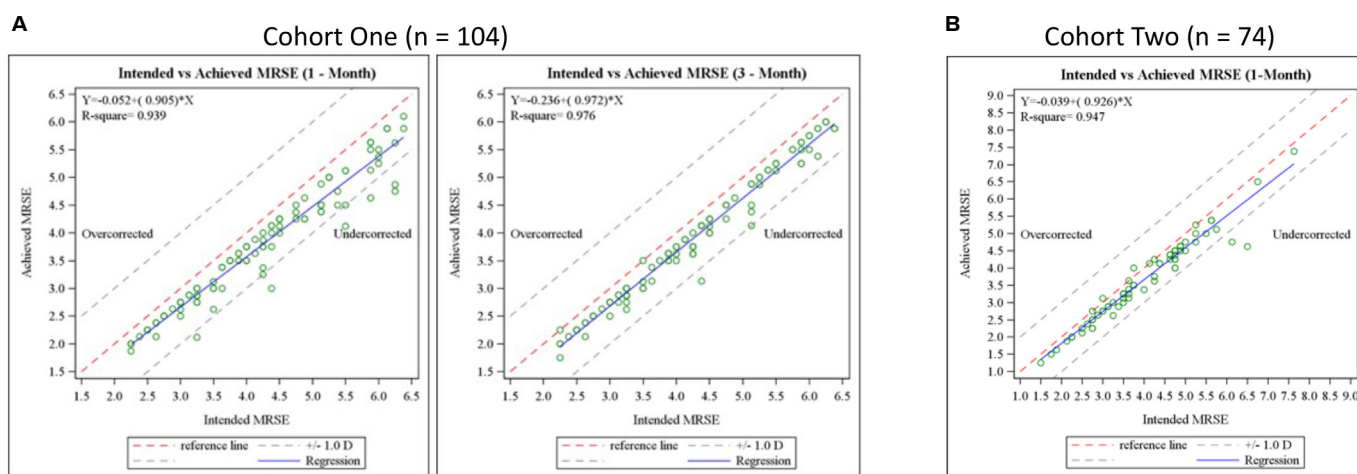


FIGURE 3: VISUAL OUTCOMES FOLLOWING SILK FOR THE TREATMENT OF MYOPIA WITH OR WITHOUT ASTIGMATISM IN TWO PATIENT COHORTS. A NOMOGRAM WAS IMPLEMENTED IN COHORT TWO. COURTESY OF ROHIT SHETTY, DNB, FRCS, PHD.



Updates to Small Incision Lenticule Extraction in Routine Practice

WALTER SEKUNDO, MD, PHD

Small incision lenticule extraction (SMILE) has been in clinical practice in Europe for more than a decade. In this time, it has undergone several optimisations and advancements to become the most mature LE technique we have today. The next-generation VisuMax 800 femtosecond laser platform (Carl Zeiss Meditec) is the most recent upgrade to this technique, designed to make lenticule creation faster, reduce the learning curve for surgeons, and further improve postoperative visual recovery.

A next-generation laser

The VisuMax 800 connects to the newly introduced refractive workplace software, which runs on the FORUM data management solution (Carl Zeiss Meditec). The software is designed to easily manage, evaluate, store, and transfer data. Patient data management and treatment planning can be performed any time prior to surgery, which is extremely useful in high-volume, busy practices as it streamlines workflow and reduces the number of administrative tasks in the operating theatre. All relevant operating procedure documentation, including all videos, generated before and after the laser treatments are assigned to each patient and stored after confirmation in the workplace software. For surgeons who don't have personalized nomograms the new laser is equipped with a nomogram tool; however, users of the previous model can continue to use their personalized nomograms, and adjust if needed.

The VisuMax 800 does not have a suction ring, only a curved lens/patient interface. In contrast to the older ma-

chine, the new laser has two moveable arms to make all the adjustments, instead of all adjustments instead of moving the patient's bed. Additionally, cyclotorsion control and centration aid are included. The former is particularly helpful if the patient has a significant amount of astigmatism. I typically mark patients with astigmatism higher than 1.5 D, first at the slit lamp and then while supine with a spatula. By marking this astigmatism, the cyclotorsion alignment system can automatically recalculate the treatment pattern and counter any cyclotorsion that occurs. There is no need to physically turn the suction cone as surgeons may have previously done (off-label). The centration aid system utilises pupil recognition for centration alignment, which is performed before the eye is docked, eliminating the need to alter the cutting pattern after docking. Given these additional features in a device full of electronics, it is perhaps not surprising that the new femtosecond laser has a longer start-up time at the beginning of the surgical day than its predecessor.

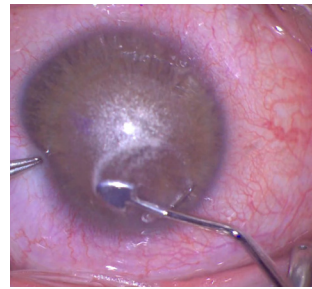


FIGURE 4: USING A SPADE-SHAPED SPATULA CAN IMPROVE THE EFFICIENCY OF LENTICULE DISSECTION BY CUTTING ON THE FORWARD AND BACKWARD STROKES, THEREBY DECREASING THE RISK OF CREATING LENTICULE REMNANTS PARTICULARLY IN THE JUXTAINCISIONAL SPACE. COURTESY OF WALTER SEKUNDO, MD, PHD.

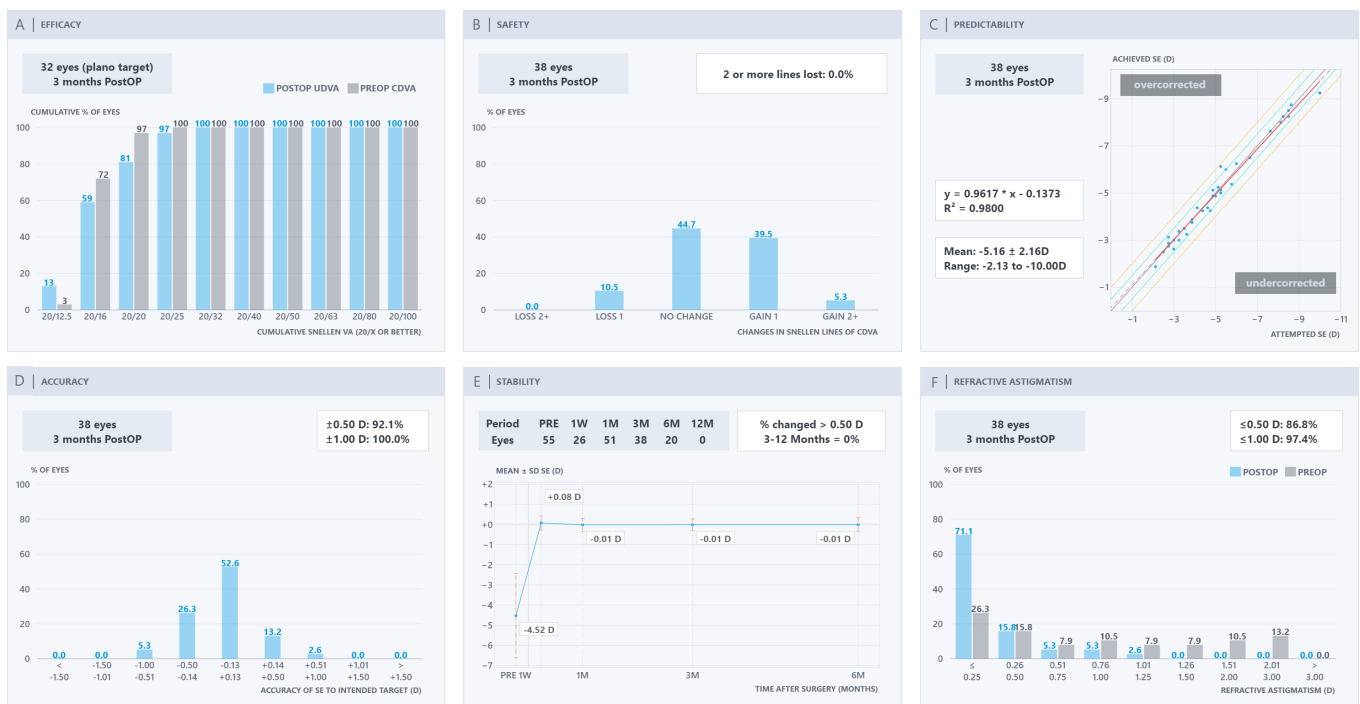

FIGURE 5: CLINICAL OUTCOMES OF MYOPIC SMILE WITH THE VISUMAX 800 FEMTOSECOND LASER. COURTESY OF WALTER SEKUNDO, MD, PHD.

The biggest improvement is that lenticule creation is three times faster than the previous model, i.e., 9 seconds for a 6.5 mm zone. This step has gotten progressively faster with every iteration of SMILE which, at the very beginning of our development of the technology 14 years ago, clocked in at 45 seconds.

While the dissection itself is not vastly different to the known SMILE procedure, I now prefer to work through a 2.5-mm incision, as a 2-mm incision resulted in too many tears at the edges. We know that lenticule remnants can be an issue, as the lenticule is thinner at the periphery. However, the juxtainscisional space is the most problematic part of the dissection. To mitigate this risk, I developed a spade-shaped spatula, which can dissect on the forward and backward strokes (Fig. 4).

Clinical outcomes of myopic SMILE

Our practice is part of an ongoing multicentre post-marketing study for the VisuMax 800. In my patient cohort, I continued to use the personalized nomograms that I first developed with the VisuMax 500, over 1000 eyes. To date, no refractive retreatments were required; however, one photorefractive keratectomy was performed after a SMILE procedure was aborted due to black spots in the interface.

In my interim outcomes, out of the 32 eyes that were targeted for plano, 81% and 59% of eyes achieved an uncorrected distance visual acuity (UDVA) of at least 20/20 and 20/16, respectively, by postoperative month 3. Almost all eyes achieved a UDVA of at least 20/25 (Fig. 5A). In terms of safety, 10.5% of eyes lost 1 line, 44.7% had no change, 39.5% gained 1 line, and 5.3% gained 2 or more lines (Fig.

5B). There was also very little undercorrection even when trying to correct -9 or -10 D (Fig. 5C). Approximately 92% of eyes were within ± 0.5 D of the intended target (Fig. 5D). The high stability of the refractive outcome has always been a major strength of the procedure, and this was also observed with this cohort (Fig. 5E). Finally, most eyes had ≤ 0.50 D of refractive astigmatism, with 71.1% achieving ≤ 0.25 D and a few dropouts that had ≥ 1.00 D of astigmatism (Fig. 5F).

The high stability of the refractive outcome has always been a major strength of the procedure

In comparison to the older femtosecond laser platform, the VisuMax 800 offers faster lenticule creation, cyclotorsion alignment, centration aid, axial alignment, a better slit-lamp, and a microscope foot pedal. Future developments will include automatic iris recognition, which will help further standardise the procedure, and a potential approval for the treatment of hyperopia.

Prof. Walter Sekundo is the Chairman of the Department of Ophthalmology at Philipps University of Marburg, Germany. He can be contacted at sekundo@med.uni-marburg.de

Prof. Sekundo is a consultant for Carl Zeiss Meditec.



The SmartSight Choice for Refractive Lenticule

VICTOR DERHARTUNIAN, MD, FEBO

The SmartSight procedure with the ATOS femtosecond laser (Schwind eye-tech-solutions GmbH) works in the plasma-mediated ablation regime. This is below the photodisruption regime and slightly above the threshold for laser-induced optical breakdown.¹ The treatment is made more accurate by the lower energy laser (below 100 nJ) and high repetition rates (several MHz).

As with other LE platforms, the platform also includes automated cyclotorsion compensation. Video-based eye tracking is used to counteract cyclotorsion, utilizing the diagnostic image as a reference. A novel feature is that centration is eye tracker-guided and semi-automated. The system displays yellow and green crosses, which mark the target centre and centre of the pupil, respectively. The green cross is first adjusted using a joystick and then by giving the patient instructions to move the eye gaze in the desired direction. If the yellow and green crosshairs are not within 200 μ m of each other, a docking error occurs, and suction cannot be applied (Fig. 6).

The SmartSight profile includes a refractive progressive transition zone, which tapers the lenticule towards the edge of the transition zone, reducing the thickness of the lenticule in the periphery to zero. This ensures that there is minimal epithelial remodelling. In practice, however, I recommend

novice surgeons start with a lenticule thickness of 80-90 μ m. With more experience and confidence with the platform, a lenticule thickness of 50 μ m or less is achievable. After 1.5 years using this platform and having performed around 400 procedures, I have only recently started treating patients with 1.5 D of myopia (less than 35 μ m thickness).

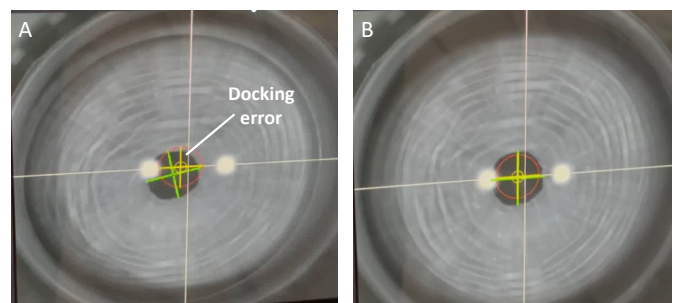


FIGURE 6: ATOS USER INTERFACE DEMONSTRATING CENTRATION/CYCLOTORSION CONTROL. (A) GREEN CROSS IS NOT WITHIN THE YELLOW CIRCLE WHICH DENOTES 200 μ m FROM THE INTENDED CENTRE, THUS LEADING TO A DOCKING ERROR. (B) BOTH GREEN AND YELLOW CROSSES ARE SUPERIMPOSED, ALLOWING THE SURGEON TO INITIATE SUCTION AND PROCEED WITH THE SMARTSIGHT TREATMENT. COURTESY OF VICTOR DERHARTUNIAN, MD, FEBO.

During the laser procedure, it is crucial to monitor treatment progress on the screen. Treatment duration is currently 45 seconds (suction on-suction off), of which less than 20 seconds includes laser use. This is longer than some other LE platforms; however, it will soon be reduced to approximately 30 seconds. Due to the relatively longer overall treatment time, there may be an increased risk for suction loss or inward conjunctival movement. It's important to keep the patient's head still by using your hands for support. Talking to the patient throughout the procedure, i.e., verbal anesthesia, can also reduce the risk of suction loss.

As with any new procedure, novice surgeons can expect consistently good visual outcomes with practice.

While there is no defined strategy for lenticule extraction, most surgeons develop their own approach with continued practice, with the goal of extracting the lenticule as gently and quickly as possible. On average, this step can take between 30 and 40 seconds. Keeping epithelial integrity and minimising the size of the incision is of utmost importance. Common problems at this stage, particularly for those newer to the procedure, can be finding the correct plane of separation or, indeed, incomplete plane separation. I typically extract the lenticule in two motions, first separating the anterior cap and then the posterior surface.

As with any refractive procedure, there is a risk that some patients will not achieve their postoperative target refraction. As such, in preoperative discussions, always make sure to explain the re-treatment strategy, if needed, and provide an estimate of the earliest that it can be performed.

A case example: Patient undergoing LE for myopia with high astigmatism

In this case of a 36-year-old man with 2 D of myopia, 4.5 D of astigmatism at a 170° axis in the right eye, the lenticule parameters were as follows: 7.5 mm optical zone, 8.3 mm total zone, 150 µm maximum thickness, and 140 µm cap thickness. The incision width was 2.8 mm, orientation and angle were 135°, and cap diameter was 9.0 mm. All corneal parameters can be imported from the manufacturer's topographer and Scheimpflug camera or from the manufacturer's spectral domain optical coherence tomographer and topographer. No nomogram was applied for the treatment. The laser energy was 80 nJ, with a spot spacing of 3.8 µm, and track distance of 2.5 µm, leading to a 0.8 J/cm² dose and applying 66 mW of average laser power.

At postoperative month 6, the patient had a residual refractive error of -0.25 spherical D with no astigmatism. The optical zone, as measured by topography, was 7.4 mm, which is close to the programmed optical zone (Fig. 7A). The corneal wavefront image shows almost no increase in coma at a pupil size of 6 mm (Fig. 7B).

As with any new procedure, novice surgeons can expect consistently good visual outcomes with practice. If early results are suboptimal, keep adjusting your surgical technique and laser settings. In my experience, once these pieces of the puzzle are in place, most postoperative outcomes on day 1 are 0.0 logMAR (20/20), rarely falling below 0.1 logMAR (20/25).

Dr. Victor Derhartunian is an Ophthalmologist and LASIK Surgeon at EyeLaser, Austria and Switzerland and SwissLaser in Poland. He can be contacted at vderhart@yahoo.com

Dr. Derhartunian has served as a consultant for Schwind eye-tech-solutions GmbH

REFERENCES:

1. Pradhan KR, Mosquera SA. Twelve-month outcomes of a new refractive lenticular extraction procedure. *J Optom.* 2021. In Press.

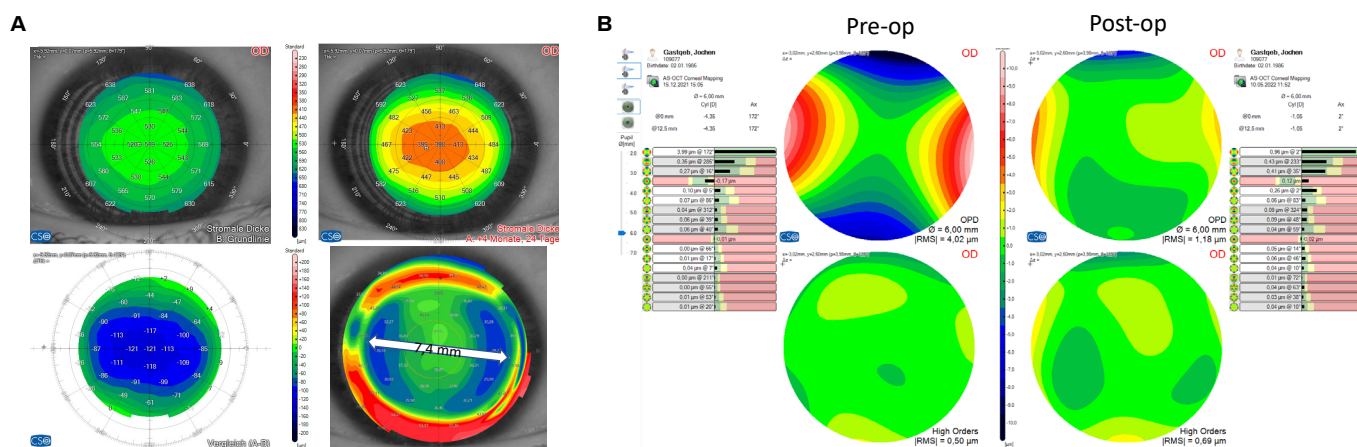


FIGURE 7: CASE STUDY OF 36-YEAR-OLD MYOPE WITH HIGH ASTIGMATISM. (A) EVALUATION OF THE POSTOPERATIVE EFFECTIVE OPTICAL ZONE BASED ON PACHYMETRIC MAP. (B) POSTOPERATIVE WAVEFRONT CHANGE AFTER SMARTSIGHT TREATMENT (OPTICAL ZONE 7.5 MM). COURTESY OF VICTOR DERHARTUNIAN, MD, FEBO.

Supported by an independent medical education grant from Johnson & Johnson Vision, Zeiss and Schwind